



Research Article

Clinical Characteristics and Therapeutic Management of Osteogenesis Imperfecta in Iraqi Children

Nabeeha Najatee Akram^{1*}, Matheel Mohammed Jaafar², Shaymaa Khalid Abdulqader³, Wassan Nori⁴,
Mustafa Ali Kassim Kassim⁵, Alexandru Cosmin Pantazi⁵

¹Department of Pediatrics, College of Medicine, Mustansiriyah University, Baghdad, Iraq; ²Department of Pediatrics, Central Child Teaching Hospital, Baghdad, Iraq; ³Department of Radiology, Al-Kindy College of Medicine, University of Baghdad, Baghdad, Iraq; ⁴Department of Obstetrics and Gynecology, College of Medicine, Mustansiriyah University, Baghdad, Iraq; ⁵Faculty of Medicine, "Ovidius" University of Constanta, 900470 Constanta, Romania

Received: 25 November 2023; Revised: 20 December 2023; Accepted: 22 December 2023

Abstract

Background: Osteogenesis imperfecta (OI) is a rare congenital condition that results in bone fragility, recurrent fractures, and various extra-skeletal manifestations. Currently, intravenous bisphosphonate is the mainstay of medical treatment in OI. **Objective:** To identify the effect of current management strategies on Iraqi children diagnosed with OI. **Methods:** A retrospective study enrolled OI patients who were registered in Central Child Teaching Hospital, Baghdad, Iraq from January 2015 to December 2022. We enrolled confirmed OI cases (either clinically and/or radiologically) who received cyclic pamidronate therapy for at least 3 cycles. They neither received other types of bisphosphonates nor underwent surgical intervention. **Results:** A total of 52 cases of OI had been identified, but only 36 patients were eligible for the current study. The mean age of the patients was 6.64±4.22 years. A statistically significant drop in the annual fracture rate in OI patients who received intravenous pamidronate cycles was seen, along with a significant rise in weight for age Z-score, lumbar spine bone mineral density DEXA Z-score, and alkaline phosphate levels. No significant improvement was documented in height for age Z-score in OI patients. **Conclusions:** Intravenous pamidronate cycles to Iraqi children with osteogenesis imperfecta works to lower their risk of breaking bones every year and raise their weight, lumbar spine bone mineral density, and alkaline phosphate levels. Pamidronate did not result in an improvement in the height of OI children.

Keywords: Children, Bisphosphonates, Osteogenesis imperfecta, Pamidronate.

الخصائص السريرية والإدارة العلاجية لتكوين العظم الناقص لدى الأطفال العراقيين

الخلاصة

الخلفية: تكون العظم الناقص (OI) هو حالة خلقية نادرة تؤدي إلى هشاشة العظام والكسور المتكررة والعديد من المظاهر خارج الهيكل العظمي. حالياً، البيفوسفونيت الوريدي هو الدعامة الأساسية للعلاج الطبي في OI. **الهدف:** تحديد تأثير استراتيجيات الإدارة الحالية على الأطفال العراقيين الذين تم تشخيص إصابتهم ب OI. **الطريقة:** سجلت دراسة بأثر رجعي مرضى OI المسجلين في مستشفى الأطفال التعليمي المركزي، بغداد، العراق من يناير 2015 إلى ديسمبر 2022. قمنا بتسجيل حالات OI المؤكدة (إما سريرياً و/أو إشعاعياً) الذين تلقوا علاج باميدرونات دوري لمدة 3 دورات على الأقل. ولم يتلقوا أنواعاً أخرى من البيفوسفونيت ولم يخضعوا للتدخل الجراحي. **النتائج:** تم تحديد ما مجموعه 52 حالة من OI، ولكن 36 مريضاً فقط كانوا مؤهلين للدراسة الحالية. كان متوسط عمر المرضى 4.22 سنة. لوحظ انخفاض ذو دلالة إحصائية في معدل الكسر السنوي في مرضى OI الذين تلقوا دورات باميدرونات عن طريق الوريد، إلى جانب ارتفاع كبير في الوزن بالنسبة للعمر Z-score، وكثافة المعادن في عظام العمود الفقري القطني DEXA Z-score، ومستويات الفوسفات القلوي. لم يتم توثيق أي تحسن كبير في الطول بالنسبة للعمر Z-score في مرضى OI. **الاستنتاجات:** تعمل دورات الباميدرونات الوريدية للأطفال العراقيين المصابين بتكوين العظم الناقص على تقليل خطر كسر العظام كل عام ورفع وزنهم وكثافة المعادن في عظام العمود الفقري القطني ومستويات الفوسفات القلوي. لم يود باميدرونات إلى تحسن في ارتفاع أطفال OI.

* **Corresponding author:** Nabeeha N. Akram, Department of Pediatrics, College of Medicine, Mustansiriyah University, Baghdad, Iraq; Email: nabiha@uomustansiriyah.edu.iq

Article citation: Akram NN, Jaafar MM, Abdulqader SK, Nori W, Kassim MAK, Pantazi AC. Clinical Characteristics and Therapeutic Management of Osteogenesis Imperfecta in Iraqi Children. *Al-Rafidain J Med Sci.* 2023;5(Suppl 1):S189-194. doi: <https://doi.org/10.54133/ajms.v5i1S.416>



INTRODUCTION

The type I collagen gene (COL1A1 or COL1A2) mutations that cause osteogenesis imperfecta (OI), a rare congenital condition that causes bone fragility and recurrent fractures. In OI, other connective tissues also don't work right, which can show up in a lot of different ways outside of the skeleton, such as dentinogenesis imperfecta, blue sclera, short stature, and hearing loss [1]. Although the precise incidence of OI in Iraq is unknown, the literature estimates that 1 in 15,000–20,000 live births is affected [2]. The therapeutic management of OI patients includes a multidisciplinary approach to address extra-skeletal manifestations in addition to fractures, decreased mobility, growth, and bone discomfort [3]. There are no curative treatments for OI [4–6]. Typically, orthopedic surgeries and medications were used to treat OI; nevertheless, the implications of the disease require pharmacological intervention to reduce bone fragility [7]. Currently, bisphosphonates represent the mainstay of medical treatment in OI; new strategies, such as sclerostin inhibitory antibodies, are explored to address the low bone mineral density and inherent bone fragility [8,9]. The underlying mechanism for bisphosphonates in children with OI is mediated at different levels. It was observed that bisphosphonates achieve their therapeutic action by permitting the joining of bony surfaces in contact with osteoclasts and increasing the apoptosis of osteoclasts. Additionally, it increases the calcium affinity of bone [10]. Different forms of bisphosphonate are available (oral and parenteral), and all were proved to be effective in children with OI, but there is no agreement regarding the exact dose, form, and duration of therapy [11–13]. Since 1998, intravenous bisphosphonate (Pamidronate) beneficial role in moderate and severe OI cases were reported; it improved bone mass, lessened fracture risk and bone pain, and improved quality of life [14]. Different studies indicated that intravenous bisphosphonate is superior to the oral form in efficacy [12,13]. Consequently, European Medicines Evaluation Agency (EMA) and Food and Drug Administration (FDA) approved the use of intravenous administration in the treatment of OI [15]. The management of osteogenesis imperfecta presents considerable challenges in Iraq. Low-resource countries usually have inadequate diagnostic resources, a lack of national clinical guidelines, and a lack of accessible, efficient therapies [16]. Previously published case reports of children with OI in Iraq were merely discussing the clinical presentation of this disease, and none had evaluated the efficacy of the current management practice implemented in Iraq for this disease [17]. This study aims to identify the results of current management practices in children diagnosed with OI in Iraq regarding assessing fracture risk, child weight, height, and bone mineral density.

METHODS

Study design

From January 2015 to December 2022, all patients with osteogenesis imperfecta registered at the Central Child Teaching Hospital in Baghdad, Iraq, were included in a retrospective study. Patients with clinically and/or radiologically diagnosed osteogenesis imperfecta who received cyclic intravenous pamidronate therapy (at least 3 cycles) were eligible. They did not receive any other types of bisphosphonates or undertake any surgical procedures. Cases that declined to participate and had incomplete or missing data were excluded. Patients were enrolled in the study after providing informed consent and explaining the purpose of the research. The local research ethics committee of Mustansiriyah University's College of Medicine approved the study (No. 10/2022).

Study population

Initially, 52 cases were reported with clinical and/or radiological diagnoses of OI. Genetic testing was not performed due to the unavailability of tests. In the studied group, 11 cases were excluded due to missing data in the medical records, and 5 cases received other forms of bisphosphonate. The total number of cases remaining eligible for the study was 36. Data was recorded using information from personal medical files (radiographic exams and medical records).

Interventions and treatment

Three sets of data were recorded for every child: clinical, biochemical, and radiological. Clinical characteristics were obtained from the patient's medical records, including anthropometric indices at diagnosis. Height and weight measurements were presented as age and sex-specific Z-scores. Serum levels of alkaline phosphatase were obtained at each visit after overnight fasting. A dual-energy X-ray absorptiometry (DEXA) scan was used to measure the bone mineral density (BMD) of the lumbar spine's L1-L4 region. This scan was done on all patients before they started treatment and at their last visit, using a STRATOS device (Ver. V3. 0.8). Bone mineral density (BMD) of the lumbar spine was presented as a Z-score to compare patient results with those of children of the same age and gender [18,19]. Intravenous Pamidronate (90 mg/vial) was administered three consecutive days every four months at a dose of 1 mg/kg/day and in a cumulative dose of 9 mg/kg/year. Pamidronate was diluted in a normal saline (0.9% NaCl) solution and infused over 2 hours. The treatment was followed by a calcium gluconate infusion of 1 ml/kg to a maximum of 10 ml per dose. None of the patients in this study received other forms of bisphosphonate or underwent orthopedic interventions in the form of intramedullary rodding surgery. All patients kept on daily oral calcium and vitamin D supplementation, both adjusted according to serum vitamin D levels.

Statistical analysis

Statistical analysis was performed using SPSS software version 26.0. Categorical data are expressed as numbers and percentages. Normally distributed data were expressed as Mean±SD and paired *t*-tests were used to compare clinical, biochemical, and densitometric variables before and after treatment. A *p*-value less than 0.05 was considered as statistically significant.

RESULTS

The number of bone fractures per 12-month period served as the basis for calculating the annual fracture rate. In the studied group, the mean age of patients was 6.64 ± 4.22 years (range 1–16 years). Females represented 56% of cases. Positive family history for the same condition was documented in 61.1% of cases, and positive consanguinity was reported in 83.3% of cases (Table 1).

Table 1: Demographic data of patients with osteogenesis imperfecta (*n*=36)

Variables	Number (%)
<i>Age (year)</i>	
≤1	4(11)
2-5	8(22)
6-9	16(44)
≥10	8(22)
<i>Gender</i>	
Male	20(56)
Female	16(44)
<i>Consanguinity</i>	
Positive	30(83.3)
Negative	6(16.7)
<i>Family history of similar condition</i>	
Negative	22(61.1)
Positive	14(38.9)
<i>Age at diagnosis</i>	
Prenatal	8(22)
At birth	16(44)
During the first year of life	6(17)
After the first year of life	6(17)
<i>Clinical manifestations at diagnosis</i>	
Blue sclera	34(94.4)
Bone Fracture	34(94.4)
Abnormal teeth	24(66)
Short stature	29(80)
<i>Site of fracture before treatment*</i>	
Femur	28(70)
Radius, ulna	18(50)
Tibia	16(44)
Humerus	12(33)
Rib	8(22)
<i>Number of Pamidronate cycles</i>	
3-5	12(33)
6-8	8(22)
9 and more	16(44)
<i>Age at the onset of treatment</i>	
The first year of life	16(44)
Second year and beyond	20(56)

*More than one site of fracture can present in the same patient.

The most prevalent time of diagnosis for the patients was during the neonatal period (44%), while prenatal diagnosis was made in only 22% of cases. The blue

sclera was the most prevalent clinical characteristic reported at diagnosis (94.4%). At the time of the study, blue sclera remained the most prevalent clinical manifestation, and skin bruises were the least common diagnostic finding, present in only 2 subjects. Femur fracture was the most common fracture documented before the start of pamidronate therapy, seen in 70% of cases, while rib fracture was observed only in 8 cases (22%). A significant number of patients (44%) received nine or more cycles of pamidronate therapy, and more than half of the patients (56%) started therapy after the first year of life, as seen in Table 1 and Figure 1.

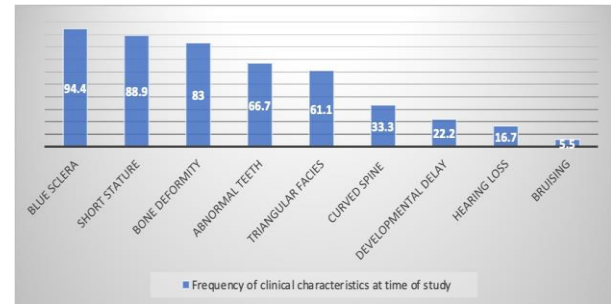


Figure 1: Clinical characteristics of children with OI at the time of the study.

During the study, intravenous Pamidronate resulted in a statistically significant decrease in the annual fracture rate in patients with OI ($p=0.001$). There were significant improvements in the patient's annual fracture rate ($p=0.001$), weight for age Z-score ($p=0.014$), lumbar BMD DEXA Z-score ($p=0.03$) and alkaline phosphate levels ($p=0.001$). Height for age Z-score improved after Pamidronate administration ($p=0.284$), as shown in Table 2.

Table 2: Changes in clinical and imaging characteristics in response to intravenous Pamidronate

Variables	Before treatment	After treatment	<i>p</i>
DEXA Z- score	-2.63±1.62	-1.96±1.28	0.03
Height for age Z-score	-8.65±44.43	-7.163±2.59	0.284
Weight for age Z-score	-4.49±2.31	-1.81±2.67	0.014
Annual fracture rate	8.2±4.87	2.28±3.0	0.001

Values are presented as mean±SD. DEXA: dual-energy x-ray absorptiometry.

The changes in biochemical criteria before and after the treatment are described in Table 3. In response to intravenous Pamidronate, a significant reduction ($p<0.001$) was observed in serum ALP (293 ± 40.7 vs. 248 ± 51.18), serum calcium (3.84 ± 0.19 vs. 2.53 ± 0.05), and serum phosphorus (1.67 ± 0.03 vs. 1.59 ± 0.1). The mean calcium level before each Pamidronate administration was 2.97 ± 1.8 mmol/l, and at the end of the cycle, it was 2.53 ± 1.23 ($p=0.045$). The mean phosphorous level before each cycle was 1.67 ± 0.73 mmol/l, and at the end of the cycle, it was 1.59 ± 0.94 ($p=0.041$). More than half of the patients had vitamin D deficiency (55%).

Table 3: Changes in biochemical values in response to intravenous pamidronate

Variables	Before treatment	After treatment	<i>p</i>
ALP (U/L)	293±40.7	248± 51.18	0.001
Calcium (mmol/l)	3.84±0.19	2.53±0.05	0.045
PO4 (mmol/l)	1.67±0.03	1.59±0.1	0.041

Values are presented as mean±SD. ALP: alkaline phosphatase; U/L: unit per liter.

DISCUSSION

This is the first Iraqi study that discusses the clinical characteristics and treatment practice patterns for pediatric patients with osteogenesis imperfecta without Iraqi evidence-based guidelines. Patients' characteristics were according to the results reported in other studies worldwide. Analysis revealed that the current practice of intravenous Pamidronate cycles administered to patients with OI resulted in significant improvements in patient annual fracture rate, weight for age Z-score, lumbar BMD DEXA Z-score, and alkaline phosphate levels. The height for age Z-score improved after Pamidronate intravenous administration. Most of the patients were born in consanguineous marriages (83.3%), as also reported by Mrosk *et al.* [20]. Iraq is well known for its high rate of consanguineous marriage, which increases the risk of hereditary diseases [21]. OI is an example, as it is inherited as autosomal dominant or less commonly autosomal recessive [22,23]. On the other hand, family history for similar conditions was positive only in 38.9% of cases. This percentage is lower than results reported in other studies; new mutations could explain this disparity [20]. According to Greeley *et al.* [24], blue sclera was the most prevalent clinical characteristic at the time of diagnosis in children with OI (94%). It was observed that 44% of patients with OI were diagnosed at the time of birth, which represents the most frequent time for diagnosis, followed by prenatal diagnosis (22%), as also suggested by other studies [24]. Intravenous Pamidronate cycles resulted in a statistically significant decrease in the fracture rate in OI children ($p=0.001$) in accordance with previous studies [25–28]. However, this finding cannot be attributed merely to the Pamidronate therapy, as the current study did not include OI patients who did not receive Pamidronate as a control group. Additionally, it is well known that fracture rates decrease with aging in OI cases [29]. Serum levels of alkaline phosphatase were significantly decreased on Pamidronate therapy, according to previous studies [29–30]. Serum alkaline phosphatase is not a good way to find out if a child with OI has osteoporosis [7]. Other biological tests, like bone alkaline phosphatase, osteocalcin, and β -cross laps, are better at finding osteoporosis and how well it responds to treatment [10]. Marginean *et al.* suggested using bone alkaline phosphatase and serum osteocalcin as markers of turnover to help diagnose and keep an eye on kids who are being given Pamidronate intravenously [10]. However, due to the unavailability of these tests in our

medical unit, serum alkaline phosphatase was used to monitor bone turnover in this study. Children with OI who received cyclical intravenous Pamidronate had statistically significant improvement in weight for the age Z-score, but a non-significant improvement was documented in height for the age Z-score. Forin *et al.* [30] also reported results that were similar. Palomo *et al.* [31] and Zeitlin *et al.* [32] found that Pamidronate therapy administered to children with OI led to a significant height gain. This difference cannot be attributed to the surgical intervention that was implemented in addition to medical therapy in OI patients in those studies, like the insertion of metal rods into the bones of the lower extremities, as in these studies, children who had not undergone surgery were found to have faster growth during Pamidronate therapy than untreated patients [32]. The significant weight gains in patients receiving Pamidronate therapy was discussed by Zeitlin *et al.*, who proposed that pain relief leads to improved appetite. Another explanation is decreased energy expenditure, which calls for close weight monitoring in patients receiving Pamidronate therapy [32]. We observed a significant improvement in lumbar spine BMD in response to intravenous Pamidronate, which agrees with previous studies [25,26,29,33]. Pinheiro *et al.* observed a delay in improvement in lumbar spine BMD after the fourth year of treatment [25]. Forin *et al.* reported an increased lumbar spine BMD of 55.4% with significant improvement in Z-scores [30]. Åström *et al.* reported a significant increase in BMD at the spine [29]. Our patients performed DEXA imaging only two times (before the start of Pamidronate therapy and after the last cycle). This is obviously because of the cost of the test. Current practice in other countries is that patients have DEXA annually, and Pamidronate dose adjustments are made accordingly [34]. In children with OI, monitoring vitamin D and calcium levels is vital as they represent an important component of the skeleton, and their deficiency can aggravate osteopenia in OI [35]. Osteopenia in children is defined as a lumbar spine BMD Z score lower than 2.0 [36]. OI patients are liable for vitamin D deficiency due to decreased outdoor activity [11]. This matches the results of our study, as 55% of patients had low vitamin D levels even though all cases received vitamin D as oral supplementation. Many treating physicians are cautious about giving high doses of vitamin D due to hypervitaminosis D risk, hypercalciuria, and subsequent nephrocalcinosis [11]. Our results showed a significantly decreased serum calcium and phosphorus level after each cycle; this goes with the results of previous studies [25,37]. Future studies should address the missing gaps in the literature regarding Pamidronate. To begin with, studies addressing pamidronate's long-term side effects, including renal impairment, osteonecrosis of the mandible, and atypical fractures, are scarce compared to its short-term benefits [38]. There is no consensus on the optimum Pamidronate dosage and duration for

enhancing BMD, fracture prevention, and child growth [39]. It remains unclear whether these bone changes can be translated into an observed functional benefit or lower the children's disability [4,40]. Additional longitudinal studies are necessary to shed light on the benefits of pamidronate in evaluating motor function, pain levels, and overall quality of life.

Limitations of the study

The current study has several limitations. First, being a retrospective study makes it subject to a high risk of bias, particularly recall bias. Second, the COVID-19 pandemic has affected many aspects of the work field [41,42]. Third, the small group size and being a single-center study, so the result may not be globalized. Finally, the study design is another limitation as it did not include a control group, and it is challenging to find patients with OI who are not on bisphosphonate treatment. However, despite these limitations, our study is the first on this disease in Iraq, and it may promote more multi-centric studies with larger sample sizes.

Conclusion

The current practice of administering intravenous Pamidronate cycles to Iraqi children with osteogenesis imperfecta is effective in improving patients' annual fracture rate, weight, lumbar spine BMD, and alkaline phosphate levels. Pamidronate results in a trend improvement in the height of OI children.

ACKNOWLEDGEMENT

The authors thank Mustansiriyah University for supporting the project.

Conflict of interests

No conflict of interests was declared by the authors.

Funding source

The authors did not receive any source of fund.

Data sharing statement

Supplementary data can be shared with the corresponding author upon reasonable request.

REFERENCES

- Jovanovic M, Guterman-Ram G, Marini JC. Osteogenesis imperfecta: Mechanisms and signaling pathways connecting classical and rare OI types. *Endocr Rev.* 2022;43(1):61-90. doi: 10.1210/edrv/bnab017.
- Neri Morales C, Silva Amaro A, Cardona JD, Bendeck JL, Cifuentes Gaitan K, Ferrer Valencia V, et al. Osteogenesis imperfecta: A case series and literature review. *Cureus.* 2023;15(1):e33864. doi: 10.7759/cureus.33864.
- Hidalgo Perea S, Green DW. Osteogenesis imperfecta: treatment and surgical management. *Curr Opin Pediatr.* 2021;33(1):74-78. doi: 10.1097/MOP.0000000000000968.
- Ralston SH, Gaston MS. Management of osteogenesis imperfecta. *Front Endocrinol (Lausanne).* 2020;10:924. doi: 10.3389/fendo.2019.00924.
- Monti E, Mottes M, Frascini P, Brunelli P, Forlino A, Venturi G, et al. Current and emerging treatments for the management of osteogenesis imperfecta. *Ther Clin Risk Manag.* 2010;6:367-81. doi: 10.2147/tcrm.s5932.
- Alcorta-Sevillano N, Infante A, Macías I, Rodríguez CI. Murine animal models in osteogenesis imperfecta: The quest for improving the quality of life. *Int J Mol Sci.* 2022;24(1):184. doi: 10.3390/ijms24010184.
- Pileggi VN, Scalize AR, Camelo Junior JS. Phase angle and World Health Organization criteria for the assessment of nutritional status in children with osteogenesis imperfecta. *Rev Paul Pediatr.* 2016;34(4):484-488. doi: 10.1016/j.rpped.2016.02.005.
- Marom R, Rabenhorst BM, Morello R. Osteogenesis imperfecta: an update on clinical features and therapies. *Eur J Endocrinol.* 2020;183(4):R95-R106. doi: 10.1530/EJE-20-0299.
- Muñoz-García J, Heymann D, Giurgea I, Legendre M, Amselem S, Castañeda B, et al. Pharmacological options in the treatment of osteogenesis imperfecta: A comprehensive review of clinical and potential alternatives. *Biochem Pharmacol.* 2023;213:115584. doi: 10.1016/j.bcp.2023.115584.
- Marginean O, Tamasanu RC, Mang N, Mozos I, Brad GF. Therapy with pamidronate in children with osteogenesis imperfecta. *Drug Des Devel Ther.* 2017;11:2507-2515. doi: 10.2147/DDDT.S141075.
- Cho TJ, Ko JM, Kim H, Shin HI, Yoo WJ, Shin CH. Management of osteogenesis imperfecta: A multidisciplinary comprehensive approach. *Clin Orthop Surg.* 2020;12(4):417-429. doi: 10.4055/cios20060.
- Kok DH, Sakkars RJ, Janse AJ, Pruijs HE, Verbout AJ, Castelein RM, et al. Quality of life in children with osteogenesis imperfecta treated with oral bisphosphonates (Olpadronate): a 2-year randomized placebo-controlled trial. *Eur J Pediatr.* 2007;166(11):1155-1161. doi: 10.1007/s00431-006-0399-2.
- Letocha AD, Cintas HL, Troendle JF, Reynolds JC, Cann CE, Chernoff EJ, et al. Controlled trial of pamidronate in children with types III and IV osteogenesis imperfecta confirms vertebral gains but not short-term functional improvement. *J Bone Miner Res.* 2005;20(6):977-986. doi: 10.1359/JBMR.050109.
- Glorieux FH, Bishop NJ, Plotkin H, Chabot G, Lanoue G, Travers R. Cyclic administration of pamidronate in children with severe osteogenesis imperfecta. *N Engl J Med.* 1998;339(14):947-952. doi: 10.1056/NEJM199810013391402.
- Adler RA, El-Hajj Fuleihan G, Bauer DC, Camacho PM, Clarke BL, Clines GA, et al. Managing osteoporosis in patients on long-term bisphosphonate treatment: Report of a Task Force of the American Society for Bone and Mineral Research. *J Bone Miner Res.* 2016;31(1):16-35. doi: 10.1002/jbmr.2708.
- Papri N, Islam Z, Leonhard SE, Mohammad QD, Endtz HP, Jacobs BC. Guillain-Barré syndrome in low-income and middle-income countries: challenges and prospects. *Nat Rev Neurol.* 2021;17(5):285-296. doi: 10.1038/s41582-021-00467-y.
- Al Mosawi AJ. Ekman-Lobstein syndrome: Clinical, radiologic features, and the therapeutic challenge. *Glob J Orthoped Res.* 2019;2(1):1-4. doi: 10.33552/GJOR.2019.02.000529.
- El Maghraoui A, Roux C. DXA scanning in clinical practice. *QJM.* 2008;101(8):605-617. doi: 10.1093/qjmed/hcn022.
- Sheu A, Diamond T. Bone mineral density: testing for osteoporosis. *Aust Prescr.* 2016;39(2):35-39. doi: 10.18773/austprescr.2016.020.
- Mrosk J, Bhavani GS, Shah H, Hecht J, Krüger U, Shukla A, et al. Diagnostic strategies and genotype-phenotype correlation in a large Indian cohort of osteogenesis imperfecta. *Bone.* 2018;110:368-377. doi: 10.1016/j.bone.2018.02.029.
- Al-Rahal NK. Inherited bleeding disorders in Iraq and consanguineous marriage. *Int J Hematol Oncol Stem Cell Res.* 2018;12(4):273-281. PMID: 30774827.

22. Holtz AP, Souza LT, Ribeiro EM, Acosta AX, Lago RMRS, Simoni G, et al. Genetic analysis of osteogenesis imperfecta in a large Brazilian cohort. *Bone*. 2023;169:116683. doi: 10.1016/j.bone.2023.116683.
23. Akram NN, Abed MA. Indications and outcome of albumin infusion in a neonatal population: A cross sectional study. *J Med Chem Sci*. 2022;5(1):129-136. doi:10.26655/JMCHMSCI.2022.1.14.
24. Greeley CS, Donaruma-Kwoh M, Vettimattam M, Lobo C, Williard C, Mazur L. Fractures at diagnosis in infants and children with osteogenesis imperfecta. *J Pediatr Orthoped*. 2013;33(1):32-36. doi: 10.1097/BPO.0b013e318279c55d.
25. Pinheiro B, Zambrano MB, Vanz AP, Brizola E, Souza LT, Félix TM. Cyclic pamidronate treatment for osteogenesis imperfecta: Report from a Brazilian reference center. *Genet Mol Biol*. 2019;42(1 suppl 1):252-260. doi: 10.1590/1678-4685-GMB-2018-0097.
26. Ward LM, Rauch F, Whyte MP, D'Astous J, Gates PE, Grogan D, et al. Alendronate for the treatment of pediatric osteogenesis imperfecta: a randomized placebo-controlled study. *J Clin Endocrinol Metab*. 2011;96(2):355-364. doi: 10.1210/jc.2010-0636.
27. Bishop N, Harrison R, Ahmed F, Shaw N, Eastell R, Campbell M, et al. A randomized, controlled dose-ranging study of risedronate in children with moderate and severe osteogenesis imperfecta. *J Bone Miner Res*. 2010;25(1):32-40. doi: 10.1359/jbmr.090712.
28. Kusumi K, Ayoob R, Bowden SA, Ingraham S, Mahan JD. Beneficial effects of intravenous pamidronate treatment in children with osteogenesis imperfecta under 24 months of age. *J Bone Miner Metab*. 2015;33(5):560-568. doi: 10.1007/s00774-014-0618-2.
29. Aström E, Söderhäll S. Beneficial effect of long term intravenous bisphosphonate treatment of osteogenesis imperfecta. *Arch Dis Child*. 2002;86(5):356-364. doi: 10.1136/adc.86.5.356.
30. Forin V, Arabi A, Guignon V, Filipe G, Bensman A, Roux C. Benefits of pamidronate in children with osteogenesis imperfecta: an open prospective study. *Joint Bone Spine*. 2005;72(4):313-318. doi: 10.1016/j.jbspin.2004.08.011.
31. Palomo T, Fassier F, Ouellet J, Sato A, Montpetit K, Glorieux FH, et al. Intravenous bisphosphonate therapy of young children with osteogenesis imperfecta: Skeletal findings during follow up throughout the growing years. *J Bone Miner Res*. 2015;30(12):2150-2157. doi: 10.1002/jbmr.2567.
32. Zeitlin L, Rauch F, Plotkin H, Glorieux FH. Height and weight development during four years of therapy with cyclical intravenous pamidronate in children and adolescents with osteogenesis imperfecta types I, III, and IV. *Pediatrics*. 2003;111(5 Pt 1):1030-1036. doi: 10.1542/peds.111.5.1030.
33. Shah I, Goel A, Shetty NS, Johari A. Intravenous pamidronate for treatment of osteogenesis imperfecta in Indian children. *Trop Doct*. 2021;51(2):271-274. doi: 10.1177/0049475520982694.
34. Salehpour S, Tavakkoli S. Cyclic pamidronate therapy in children with osteogenesis imperfecta. *J Pediatr Endocrinol Metab*. 2010;23(1-2):73-80. doi: 10.1515/jpem.2010.23.1-2.73.
35. Chagas CE, Roque JP, Santarosa Emo Peters B, Lazaretti-Castro M, Martini LA. Do patients with osteogenesis imperfecta need individualized nutritional support? *Nutrition*. 2012;28(2):138-142. doi: 10.1016/j.nut.2011.04.003
36. Sala A, Barr RD. Osteopenia and cancer in children and adolescents: The fragility of success. *Cancer*. 2007;109:1420-1451. doi: 10.1002/cncr.22546.
37. DiMeglio LA, Ford L, McClintock C, Peacock M. Intravenous pamidronate treatment of children under 36 months of age with osteogenesis imperfecta. *Bone*. 2004;35(5):1038-1045. doi: 10.1016/j.bone.2004.07.003.
38. Hwang S, Seo M, Lim D, Choi MS, Park JW, Nam K. Bilateral atypical femoral fractures after bisphosphonate treatment for osteoporosis: A literature review. *J Clin Med*. 2023;12(3):1038. doi: 10.3390/jcm12031038.
39. Simm PJ, Biggin A, Zacharin MR, Rodda CP, Tham E, Siafarikas A, et al. Consensus guidelines on the use of bisphosphonate therapy in children and adolescents. *J Paediatr Child Health*. 2018;54(3):223-233. doi: 10.1111/jpc.13768.
40. Hill CL, Baird WO, Walters SJ. Quality of life in children and adolescents with Osteogenesis Imperfecta: a qualitative interview based study. *Health Qual Life Outcomes*. 2014;12:54. doi: 10.1186/1477-7525-12-54.
41. Akram NN, Nori W, Al Qaissi KW, Abdulrahman Hadi BA. Multi-systemic inflammatory syndrome in childhood (MIS-C): A review article. *J Pak Med Assoc*. 2021 Dec;71(Suppl 9)(12):S70-S73. PMID: 35130265.
42. Tuttle KR. Impact of the COVID-19 pandemic on clinical research. *Nat Rev Nephrol*. 2020;16(10):562-564. doi: 10.1038/s41581-020-00336-9.