

Al-Rafidain J Med Sci. 2026;10(1):236-241.
DOI: <https://doi.org/10.54133/ajms.v10i1.2722>

AJMS



Online ISSN (3219-2789)

Research Article

Outcome of Total Proctocolectomy with Ileal Pouch Anal Anastomosis Using Diverting Loop Ileostomy in Familial Adenomatous Polyposis

Noori Hanoon Jasim^{1*} , Ali Dawood Alhilfi²

¹College of Medicine, University of Basrah, Basrah, Iraq; ²Basrah Gastroenterology and Hepatology Hospital, Basrah, Iraq

Received: 2 January 2026; Revised: 22 February 2026; Accepted: 26 February 2026

Abstract

Background: Total proctocolectomy with ileal pouch anal anastomosis (IPAA) is a standard procedure for many diseases, including familial adenomatous polyposis (FAP). This procedure can be achieved by different options. **Objectives:** To report and assess the outcome of a two-stage operation: Proctocolectomy with IPAA with diverting loop ileostomy followed by ileostomy reversal as a second stage using a stapled technique for J-pouch type. **Methods:** A prospective study conducted in Basrah Gastroenterology and Hepatology Hospital from March 2022 to June 2025. It involves 10 patients (two males and 8 females) diagnosed as FAP by colonoscopy and histopathological biopsies. All patients experienced two-stage operations. Laparotomies using the stapled technique were performed for all patients. The J-pouch type was created in all of them. Follow-up for all patients was achieved by scheduled visits. **Results:** No death was reported in this study. In addition, none of the patients developed anastomotic leakage, pouch loss, impotence, pulmonary embolism, bleeding, fecal incontinence, postoperative pneumonia, or intestinal obstruction. However, the following complications were reported as follows: Pouchitis (2/10), incisional hernia (2/10), wound infection (3/10), and peristomal dermatitis (10/10). **Conclusions:** This operation successfully achieved the primary treatment of FAP without serious complications, such as leakage, which encourages further studies involving larger sample sizes and the use of various staged surgical procedures for FAP or other patients with a broader range of underlying diseases.

Keywords: Diverting ileostomy; Familial adenomatous polyposis; Ileal pouch anal anastomosis; J-pouch; Proctocolectomy.

نتائج استئصال القولون والمستقيم الكامل مع ربط كيس اللفانفي المصنع مع الحلقة الشرجية واستخدام تفويه اللفانفي التحويلي في مرض الورم الغدي السلالي العائلي

الخلاصة

الخلفية: استئصال القولون الكامل مع التشريح الشرجي في الكيس اللبائي (IPAA) هو إجراء قياسي للعديد من الأمراض، بما في ذلك تعدد الخلايا الغدية العائلي (FAP). يمكن تحقيق هذا الإجراء من خلال خيارات مختلفة. **الأهداف:** الإبلاغ عن نتيجة عملية من مرحلتين: استئصال القولون مع IPAA مع فغر اللفانفي الحلقي التحويلي، تليها عكس الإيليوستومي كمرحلة ثانية باستخدام تقنية مثبتة لنوع J-pouch. **الطرائق:** دراسة مستقبلية أجريت في مستشفى البصرة لأمراض الجهاز الهضمي والكبد من مارس 2022 حتى يونيو 2025. تشمل الدراسة 10 مرضى (ذكران وثمانى إناث) تم تشخيصهم بـ FAP من خلال تنظير القولون وخزعات نسيجية. جميع المرضى خضعوا لعمليات من مرحلتين. تم إجراء عمليات فتح البطن باستخدام تقنية الدباسة لجميع المرضى. تم استخدام J-pouch في جميعها. تمت متابعة جميع المرضى من خلال زيارات مجدولة. **النتائج:** لم يتم الإبلاغ عن أي وفاة في هذه الدراسة. بالإضافة إلى ذلك، لم يصب أي من المرضى بتسرب متحمس أو فقدان الجيب أو العجز الجنسي، أو انسداد رئوي، أو نزيف، أو سلس البراز، أو التهاب رئوي بعد العملية، أو انسداد الأمعاء. ومع ذلك، تم الإبلاغ عن المضاعفات التالية: التهاب الكيس (10/2)، فتق الشقوق (10/2)، التهاب الجرح (10/3)، والتهاب الجلد المحيطي (10/10). **الاستنتاجات:** حققت هذه العملية بنجاح العلاج الأساسي لـ FAP دون مضاعفات خطيرة مثل التسرب، مما يشجع على المزيد من الدراسات التي تشمل عينات أكبر واستخدام إجراءات جراحية مرحلية مختلفة لمرضى FAP أو مرضى آخرين يعانون من مجموعة أوسع من الأمراض الأساسية.

* **Corresponding author:** Noori H. Jasim. College of Medicine, University of Basrah, Basrah, Iraq; Email: noorihanon@yahoo.com

Article citation: Jasim NH, Alhilfi AD. Outcome of Total Proctocolectomy with Ileal Pouch Anal Anastomosis Using Diverting Loop Ileostomy in Familial Adenomatous Polyposis. *Al-Rafidain J Med Sci.* 2026;10(1):236-241. doi: <https://doi.org/10.54133/ajms.v10i1.2722>

© 2026 The Author(s). Published by Al-Rafidain University. This is an open access journal issued under the CC BY-NC-SA 4.0 license (<https://creativecommons.org/licenses/by-nc-sa/4.0/>).



INTRODUCTION

The ileal pouch–anal anastomosis (IPAA) is a standard surgical operation that is adopted to keep continuity of the gastrointestinal tract following proctocolectomy [1]. The operation includes the formation of a small intestinal pouch to replace the rectum, creating a stool reservoir after complete resection of the colon and rectum. This procedure is achieved by stapling together two or more loops of small intestine (most commonly a J pouch and much less commonly an S pouch or W pouch) [2]. This pouch is definitely anastomosed with the anus. Temporary diverting ileostomy is frequently used with IPAA, which will be closed in the next separate operation [2]. Proctocolectomy with IPAA is indicated mostly in ulcerative colitis, familial adenomatous polyposis (FAP), and toxic megacolon

[1,3]. This surgical procedure is contraindicated when the distal ileum or anus (anal canal) is often affected by underlying pathology such as Crohn's disease [4]. Proctocolectomy and IPAA can be achieved by different options. The commonest option is a staged surgical operation (two-stage and three-stage operation); the time between one stage and the other is 6-12 weeks [5]. Less commonly, a single-stage operation that is called restorative proctocolectomy, which includes proctocolectomy and IPAA without diverting proximal ileostomy [6]. In a two-stage procedure: proctocolectomy, IPAA, and creation of a diverting ileostomy as a first stage (operation) and then reversal of the diverting loop ileostomy as a second stage [5]. While the three-stage procedure is total colectomy and ileostomy as a first stage. In the second stage, the procedures include proctectomy, IPAA, and

the creation of a diverting loop ileostomy. Finally, ileostomy reversal as a third-stage operation [5]. This operation, like any other surgical operation, could have certain general complications such as hemorrhage, infection of wounds, lung infections, cardiac problems, deep venous thrombosis, and pulmonary embolism [4]. Specific complications, particularly with one-stage operations, can be classified as early and late [4]. Early complications include anastomotic leakage, which is considered a serious complication [7]. Late specific complications include anal incontinence, obstruction of the bowel, and impotence, which is occasional, and the most common late specific complication is pouchitis. Main presentations of pouchitis include fever, frequent watery diarrhea, abdominal cramps, tenesmus, and anorexia [8]. FAP syndrome is a rare genetic condition (1 in 8000 live births). It is an autosomal dominant disease with varying degrees of penetrance affecting teenagers. FAP includes hundreds to thousands of polyps all over the colorectal tract. Polyps are premalignant for colorectal cancer. Colectomy is essential for a considerable decrease in conversion to colorectal cancer [9]. To the best of our knowledge, there is no previously published work in southern Iraq reporting this procedure. The current study was designed to assess the outcomes of this procedure, particularly in serious complications such as leakage.

METHODS

Study design and setting

This prospective study was conducted from March 2022 until June 2025 in Basrah Gastroenterology and Hepatology Hospital. In the current study, 10 patients who were attending the hospital had a detailed history taken, including main clinical features. Blood investigations were performed, including complete blood count, renal function test, liver function test, random blood sugar, and CRP.

Inclusion criteria

This study included all patients who presented to our hospital with FAP disease, where the diagnosis was confirmed by colonoscopy and histopathological examination of biopsies, and who provided consent.

Exclusion criteria

Patients with FAP and histopathological exams of biopsies showing dysplasia or harboring malignancy, as well as patients with FAP and concurrent polyps in the stomach and duodenum. Patients who had undergone ileal pouch anal anastomosis for reasons other than FAP, such as severe ulcerative colitis or toxic megacolon, were excluded.

Intervention and outcome measurements

Then, imaging investigations were done in terms of ultrasonography and computerized tomography (CT). Then, specific investigations, particularly colonoscopy with endoscopic biopsies, were performed.

Consequently, disease status and its treatment were assessed. The possible complications were discussed in details including that this procedure is two-stage operation and the diverting ileostomy needs to be closed later on, in addition, possible complications of stoma like high output of ileostomy and peristomal dermatitis alongside the presumably expected benefit of ileostomy to reduce the leak possibility of IPAA, pouchitis were discussed with patients. Packed RBCs were prepared for every patient; mechanical and chemical bowel preparation was done, including laxative tablets and sachets with metronidazole tab 500 mg t.d.s. one day before surgery. Ceftriaxone vials of 1 gm were given 1 hour before starting the surgical operation. Compression stockings were used to reduce the possibility of deep venous thrombosis.

Surgical technique

Generally, under general anesthesia and with the patient in the Lloyd Davies position, a midline incision was used, and classical total proctocolectomy until the upper level of the anal canal was achieved by stapling using an Endo GIA articulating reload with tri-staples technology and a 45 mm medium/thick stapler. A 15 cm J-pouch was created by two loops that were stapled to form a pouch. Then, the ileal pouch was anastomosed with the anus using a circular stapler with tri-staple technology 29 or 31, accordingly to the DST series. Consequently, proximal diverting loop ileostomy was achieved in a proper site of the abdominal wall. Intravenous fluid, intravenous third-generation cephalosporin (particularly ceftriaxone 1 gm b.i.d.), intravenous metronidazole 500 mg vial t.d.s., intravenous paracetamol 1 gm vial b.i.d., and enoxaparin 4000 IU once daily subcutaneously were given. Patients were closely monitored during their admission in a surgical ward, particularly their vital signs, urine output, pelvic drain observation, and general status. The stomach tube was removed in the recovery room. The patient was encouraged for early mobilization on the operative night and started oral clear fluids 12 hours after surgery. Five days postoperatively, Folly's catheter was removed. The pelvic drain was removed when it was usually non-functioning or had no significant drainage and the stoma started functioning. Patients were educated about stoma care, particularly on early days when the output would be watery and frequent, by training patients about properly fixing stoma appliances and prescribing creams for peristomal skin to avoid dermatitis and skin excoriation.

Postoperative management

Follow-up was primarily scheduled as follows: after 2 weeks for stitch removal and patients' checkup. Then, after 3 months of doing barium enemas to ensure healing, exclude anastomotic leakage and plan for ileostomy closure. Then, 2 weeks after ileostomy closure. Consequently, 2 months later on to rule out any possible complications, and eventually after one year. Early follow-up included detecting any leakage of the anastomotic line by recording any temperature

elevation, severe abdominal or anal pain, or any discharge through the wound or anus, followed by ultrasonography or computerized tomography if there is suspicion of a leak. The latest follow-up included a clinical assessment of pouchitis by asking patients about main clinical features, which include fever, frequent watery diarrhea, abdominal cramps, tenesmus, and anorexia. Fecal incontinence was clinically assessed by asking patients about their ability to control gas, liquid stool, or solid stool. Male impotence was clinically assessed by asking the patients about any worsening changes in sexual activity postoperatively.

Ethical considerations

The study protocol was approved by the Ethical Committee of Basrah College of Medicine, University of Basrah, Iraq. All participants provided written informed consent. The study conducted adhered to the Declaration of Helsinki.

Data analysis

Qualitative data were expressed in terms of number and percentage, whereas quantitative data were expressed in terms of mean ± SD. Descriptive statistics was applied.

RESULTS

The current study includes 10 patients; 8 patients were females and 2 patients were males. The age ranged from 20 to 43 years old (31.8 ± 0.31 years). All of them were diagnosed as FAP by colonoscopy and endoscopic biopsies. No one included in the current study was diagnosed by histopathology as dysplasia or harboring malignancy. Moreover, none of our patients

had concurrent polyps in the stomach and duodenum, as proven by upper gastrointestinal endoscopy. Proctocolectomy with IPAA with diverting temporary loop ileostomy was performed for all patients in this study, as shown in Figure 1.

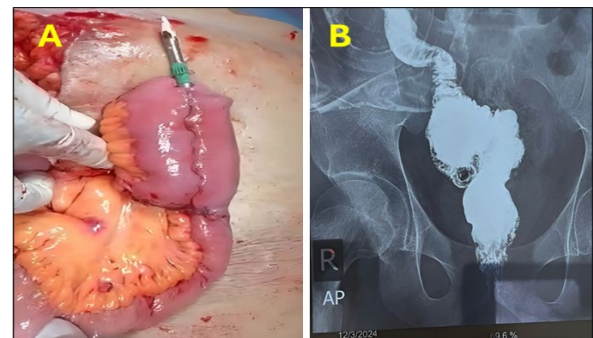


Figure 1: A) Creating J pouch by staplers, anvil of circular stapler was inserted in pouch and ready to make pouch-anal anastomosis. B) Barium Enema for IPAA three months postoperatively showing no sign of leak or stenosis reflecting the patient is ready for loop ileostomy reversal.

Then, all patients underwent ileostomy closure almost 3 months later after a water-soluble radiographic study (barium enema) to rule out the possibility of leaks. All patients received 2 units of packed RBC intraoperatively on a clinical basis in response to extensive enterectomy and 1-2 units of packed RBC postoperatively according to the hemoglobin test, with a mean of total blood transfusion of 3.1 ± 0.31 units. The hospital stay of patients was 6-7 days, with a mean of 6.5 ± 0.53 days. Fecal function (motion number) after ileostomy closure was 7-9 times/day (8.1 ± 0.88 times/day), decreasing with time to 2-3 times/day (2.5 ± 0.53 times/day) 2-3 months later on, as shown in Table 1.

Table 1: Summary of patient characteristics

Age (year)	Sex	Blood transfusion/patient	Hospital stay/patient (day)	Motions after ileostomy closure (motions/day/patient)	Motions in 2 patients with pouchitis (motions/day/person)
31.8±6.0	F 8(80) M 2(20)	3.1±0.31	6.5±0.53	Early 8.1±0.88 Late 2.5±0.53	Early 13.5±1.27 Late 5.1±0.88

Values are presented as frequency, percentage, and mean±SD.

Two patients developed pouchitis; their motions per day reached up to 12-15 times/day (13.5 ± 1.27 times/day). Both of them responded to medical treatment in terms of antibiotics in terms of ciprofloxacin 500 mg b.i.d. and metronidazole 500 mg t.i.d. for 14 days, reaching up to 4-6 motions per day with a mean of 5.1 ± 0.88 (Table 1), and none of them were fortunately reported as refractory to medical treatment. In the current study, no death was reported, and no anastomotic leakage. However, 10 out of 10 patients developed peristomal dermatitis and skin excoriation around ileostomy of variable degrees particularly during first 2-3 weeks because of high small bowel stoma output and watery in consistency, all of them treated by proper fixing of colostomy appliances and using proper creams, training patients and their families about stoma care, all of them responded well for such measures. In addition, 3

patients out of 10 developed wound infections, as shown in Table 2.

Table 2: Complications of two-stage proctocolectomy with IPAA with proximal diverting ileostomy

Complications	n(%)
Peristomal dermatitis	10(100)
Incisional hernia	2(20)
Death	0(0.0)
Pouchitis	2(20)
Pouch loss	0(0.0)
Wound Infection	3(30)
Impotence	0(0.0)
Deep Venous Thrombosis and Pulmonary embolism	0(0.0)
Anastomotic Leak	0(0.0)
Intestinal obstruction	0(0.0)
Bleeding	0(0.0)
Early post-operative Pneumonia	0(0.0)
Fecal incontinence	0(0.0)

Pouchitis was developed in 2 out of 10 patients; they were clinically detected by frequent watery diarrhea, abdominal cramps, fever, and anorexia. Incisional hernia was reported in 2 patients; both of them were surgically treated later on. But the other possible complications had not occurred, such as bleeding, pouch loss, intestinal obstruction, pulmonary embolism, anal incontinence, impotence, or early postoperative pneumonia (Table 2).

DISCUSSION

It is known that FAP is a rare disease [9], and it is of interest to report performing this procedure in our growing center, for a whole number of patients with FAP consulted our center during the period of study. One patient with FAP that converted to malignancy was not included in this study to avoid adding different other parameters supposedly affecting anastomosis healing and consequently leakage, such as malignancy and preoperative chemotherapy. In certain diseases such as FAP, the total colon and rectum must be removed (proctocolectomy), in which the rectum must be fully mobilized before division till the beginning of the anus, taking into consideration the identification and preservation of the pelvic nerves. This can be achieved by a stapler, whether straight or curved. This can be performed by open surgical abdominal operation, laparoscopy, or robotic tool operation [10-13]. All patients in the current study underwent proctocolectomy by laparotomy and using staplers without hand sewing. It is reported that this operation could be achieved by a single stage [6]. However, many other centers achieved this operation in two stages [5], thinking that diverting ileostomy leads to better healing and maturation of the pouch and thus decreases the possibility of leakage while the ileostomy diverts the fecal stream [14]. Hence, in the current study, this option was adopted to possibly reduce the serious complications, such as leakage, in our evolving center. Furthermore, other centers performed this operation using a three-stage procedure [5]. It is reported that this option is preserved in certain conditions such as severe ulcerative colitis severely affecting the colon and rectum, and this could be achieved either transanally or transabdominally [15,16]. Moreover, there is a modified two-stage proctocolectomy that consists of subtotal colectomy accompanied with end ileostomy, then completion proctectomy and creation of IPAA but not accompanied with diverting ileostomy, and it is thought to be more used in severe cases of ulcerative colitis and has a lower rate of anastomotic leakage in comparison to traditional two-stage IPAA [17]. It is already known that there are different types of ileal pouches, such as the J-pouch, which is the typical one and thus was performed in the current work, and occasionally the S-pouch or W-pouch. In all types the ileal loops are anastomosed to each other either by hand sewing or GIA staplers, forming a reservoir that is preferably 15-20 cm in length [4]. Kirat et al. [18] have observed a better result of the stapled method over the hand swing one; thus, it was chosen for all patients

in the present work. However, Tatsuta *et al.* reported in their multicentric study including 53 patients with FAP in 12 institutions that the 20-year overall survival rate was worse in stapled IPAA in comparison to hand-sewn IPAA due to cancer risk [19]. Bouchiba *et al.* showed in their multicentric study for almost 3 decades with a median follow-up of 12 and 15 years that 0.9% of their patients developed pouch/rectal cuff cancer following IPAA, whereas 2.2% of their patients developed such cancer following direct ileoanal anastomosis, raising the likelihood of the risk of cancer developing in the pouch/rectal cuff, necessitating long-term endoscopic surveillance and monitoring after proctocolectomy whatever the option used [20]. Like any other surgical operation, this operation might carry general complications such as early postoperative bleeding, deep venous thrombosis (DVT), pneumonia, and wound infection [4]. In our study, three patients developed wound infections, and that comes in accord with previous literature [4]. But bleeding, DVT, and pneumonia were not reported in the present study in comparison to previous literature [4]. In the current study, there was clearly no anastomotic leakage that might be attributed to performing diverting ileostomy as part of this procedure, accompanied by other possible factors in our series like patients' young age, no malignancy, or neoadjuvant chemotherapy. However, it is important to emphasize that the small number of patients in the current study limits statistical strength. In contrast to our study, Zhuo *et al.* reported in their retrospective study for 10 years that 8.2% of 244 patients in their series developed anastomotic leakage, which might require percutaneous drainage under ultrasound guidance or sometimes abdominal re-exploration [7]. Peristomal skin dermatitis was reported in all patients in our study, with variable degrees of redness, excoriation, or skin changes, particularly in the first few weeks postoperatively due to frequent and watery intestinal contents. All patients responded well to the treatment and education mentioned in the results section. In contrast, a recent study reports that the rate of peristomal skin complications is 36.3% to 73.4% [21]. This might be ascribed to the small number of patients in our study or the occurrence of complications during the period of patient training while the patient was in the early postoperative period. Brewer *et al.* reported many long-term complications, such as intestinal obstruction, fecal incontinence, and male impotence, as long-term complications for total proctocolectomy and IPAA [4]. In contrast, the absence of these complications in the current study represents a notable observation, and no patients complained of loss of ability to control passage of gas or stool; hence, there was no need for further tests or investigations for anal continence. Two male patients included in this study did not develop worse changes in their sexual activity. However, lack of fecal incontinence and male impotence in our study might be attributed to a relatively limited follow-up duration and small cohort. Incisional hernia was reported in two patients in our series, and that is similar to other studies [4]. It is considered that pouchitis is a common

complication after this procedure, reaching 50% of patients [18], whereas in the present study, the pouchitis percentage was less and noted in 2 out of 10 patients, representing 20%, and both of them responded to antibiotics. This might be attributed again to the small frequency of patients in this study. Antibiotics have been reported as first-line treatment; however, many other researchers have reported good results by using steroid or monoclonal antibody treatment for antibiotic-refractory pouchitis [22-24]. Seifarth *et al.* successfully tested sacral nerve stimulation for reduction of the number of bowel motions [25]. Patients in this study benefit from this surgical operation by successfully treating FAP via removing the affected colon and rectum and creating a pouch as an alternative to the already resected diseased rectum without any deaths or serious complications. Furthermore, because FAP is a systemic disease, gastroenterologists and physicians in our hospital provided those patients with monitoring and thorough screening clinically or endoscopically for extracolonic manifestations during or after the period of study.

Limitations of the study

Single-center study with a small sample size because of the rarity of the disease (FAP), leading to restricted statistical strength. However, the promising outcome of the IPAA procedure encourages expanding this work in patients with other indications such as certain cases of ulcerative colitis and toxic megacolon alongside newly discovered patients with FAP using different options of surgical operations with different techniques in terms of hand-sewing or using staplers to enable designing a comparative study and thus, acquiring a statistically significant clinical decision.

Conclusions

Choosing a two-stage procedure using the stapled technique was feasible and might presumably reduce the incidence of serious complications such as anastomotic leakage and pouchitis. In addition, a stapled J-pouch was a reasonable option. However, the sample size needs to be expanded in the future to enable comparing different surgical options and thus, statistically enforce the clinical conclusion.

Recommendation

In spite of the satisfactory outcome, it is planned to include more patients in such similar future work using different surgical options to achieve total proctocolectomy with IPAA for FAP with one-stage, two-stage, modified two-stage, three-stage procedures, or direct ileoanal anastomosis accordingly and to make a comparative study. A multicentric study will be planned in the future to strengthen statistical significance.

ACKNOWLEDGMENTS

The authors are grateful to all patients who agreed to participate in this study.

Conflict of interests

The authors declared no conflict of interest.

Funding source

The authors did not receive any source of funds.

Data sharing statement

Supplementary data can be shared with the corresponding author upon reasonable request.

REFERENCES

1. Ng KS, Gonsalves SJ, Sagar PM. Ileal-anal pouches: A review of its history, indications, and complications. *World J Gastroenterol.* 2019;25 (31):4320-4342. doi: 10.3748/wjg.v25.i31.4320.
2. Remzi FH, Lavryk OA, Ashburn JH, Hull TL, Lavery IC, Dietz DW, et al. Restorative proctocolectomy: an example of how surgery evolves in response to paradigm shifts in care. *Colorectal Dis.* 2017;19(11):1003-1012. doi: 10.1111/codi.13699.
3. Tajika M, Niwa Y, Bhatia V, Tanaka T, Ishihara M, Yamao K. Risk of ileal pouch neoplasms in patients with familial adenomatous polyposis. *World J Gastroenterol.* 2013;19(40):6774-6783. doi: 10.3748/wjg.v19.i40.6774.
4. Brewer MB, Bafford AC, Roberts KE. Ileal Pouch-Anal Anastomosis Technique. *Medscape.* 2023 July 28. Available at: <https://emedicine.medscape.com/article/1892231-technique?form=fpf>.
5. Thompson DT, Hrabec JE. Staged approaches to restorative proctocolectomy with ileoanal pouch-When and why? *J Laparoendosc Adv Surg Tech A.* 2021;31(8):875-880. doi: 10.1089/lap.2021.0060.
6. Joyce MR, Kiran RP, Remzi FH, Church J, Fazio VW. In a select group of patients meeting strict clinical criteria and undergoing ileal pouch-anal anastomosis, the omission of a diverting ileostomy offers cost savings to the hospital. *Dis Colon Rectum.* 2010;53(6):905-910. doi: 10.1007/DCR.0b013e3181d5e0fd.
7. Zhuo C, Trencheva K, Maggiori L, Milsom JW, Sonoda T, Shukla PJ, et al. Experience of a specialist centre in the management of anastomotic sinus following leaks after low rectal or ileal pouch-anal anastomosis with diverting stoma. *Colorectal Dis.* 2013;15(11):1429-1435. doi: 10.1111/codi.12436.
8. Navaneethan U, Shen B. Diagnosis and management of pouchitis and ileoanal pouch dysfunction. *Curr Gastroenterol Rep.* 2010;12(6):485-494. doi: 10.1007/s11894-010-0143-y.
9. Menon G, Carr S, Kasi A. Familial Adenomatous Polyposis. The MD Searchlight Team. MD Searchlight. 2024 May 5. Available at: https://mdsearchlight.com/genetic-disorders/familial-adenomatous-polyposis/#google_vignette.
10. Jani K, Shah A. Laparoscopic total proctocolectomy with ileal pouch-anal anastomosis for ulcerative colitis. *J Minim Access Surg.* 2015;11(3):177-183. doi: 10.4103/0972-9941.140212.
11. Campos FG, Real Martinez CA, Monteiro de Camargo MG, Cesconetto DM, Nahas SC, Ceconello I. Laparoscopic versus open restorative proctocolectomy for familial adenomatous polyposis. *J Laparoendosc Adv Surg Tech A.* 2018;28(1):47-52. doi: 10.1089/lap.2017.0397.
12. Shimada N, Ohge H, Yano R, Murao N, Shigemoto N, Uegami S, et al. Hand-assisted laparoscopic restorative proctocolectomy for ulcerative colitis. *World J Gastrointest Surg.* 2016;8(8):578-582. doi: 10.4240/wjgs.v8.i8.578.
13. Morelli L, Guadagni S, Mariniello MD, Furbetta N, Pisano R, D'Isidoro C, et al. Hand-assisted hybrid laparoscopic-robotic total proctocolectomy with ileal pouch-anal anastomosis. *Langenbecks Arch Surg.* 2015;400(6):741-748. doi: 10.1007/s00423-015-1331-x.
14. Clancy C, Connelly TM, Jia X, Lipman J, Lightner AL, Hull T, et al. Defining the safety of early ileostomy closure after ileal

- pouch anal anastomosis. *Tech Coloproctol.* 2023;27(12):1257-1263. doi: 10.1007/s10151-023-02811-4.
15. Bislenghi G, Denolf M, Fieuws S, Wolthuis A, D'Hoore A. Functional outcomes of transanal versus transabdominal restorative proctectomy with ileal pouch-anal anastomosis in ulcerative colitis-a monocentric retrospective comparative study. *Langenbecks Arch Surg.* 2022;407(8):3607-3614. doi: 10.1007/s00423-022-02640-3.
 16. Vernon J, Ng D, Khan S, Koerber D, Ghuman A, Karimuddin A. Functional outcomes after transanal ileal pouch-anal anastomosis for ulcerative colitis: narrative review of the current literature. *Tech Coloproctol.* 2023;27(9):713-719. doi: 10.1007/s10151-023-02798-y.
 17. Zittan E, Wong-Chong N, Ma GW, McLeod RS, Silverberg MS, Cohen Z. Modified two-stage ileal pouch-anal anastomosis results in lower rate of anastomotic leak compared with traditional two-stage surgery for ulcerative colitis. *J Crohns Colitis.* 2016;10(7):766-772. doi: 10.1093/ecco-jcc/jjw069.
 18. Kirat HT, Remzi FH, Kiran RP, Fazio VW. Comparison of outcomes after hand-sewn versus stapled ileal pouch-anal anastomosis in 3,109 patients. *Surgery.* 2009;146(4):723-729. doi: 10.1016/j.surg.2009.06.041.
 19. Tatsuta K, Sakata M, Iwaizumi M, Okamoto K, Yoshii S, Mori M, et al. Long-term prognosis after stapled and hand-sewn ileal pouch-anal anastomoses for familial adenomatous polyposis: a multicenter retrospective study. *Int J Colorectal Dis.* 2024;39(1):32. doi:10.1007/s00384-024-04608-9.
 20. Bouchiba H, Aelvoet AS, Pellisé M, Bastiaansen BAJ, van Leerdam ME, Langers AMJ, et al; European FAP Consortium. Risk of cancer and reoperation after ileorectal anastomosis and ileal pouch-anal anastomosis in familial adenomatous polyposis. *Am J Gastroenterol.* 2024;120(9):2132-2138. doi: 10.14309/ajg.00000000000003273.
 21. D'Ambrosio F, Pappalardo C, Scardigno A, Maida A, Ricciardi R, Calabrò GE. Peristomal skin complications in ileostomy and colostomy patients: What we need to know from a public health perspective. *Int J Environ Res Public Health.* 2022;20(1):79. doi: 10.3390/ijerph20010079.
 22. Huguet M, Pereira B, Goutte M, Goutorbe F, Dubois A, Bommelaer G, et al. Systematic review with meta-analysis: Anti-TNF therapy in refractory pouchitis and Crohn's disease-like complications of the pouch after ileal pouch-anal anastomosis following colectomy for ulcerative colitis. *Inflamm Bowel Dis.* 2018;24 (2):261-268. doi: 10.1093/ibd/izx049.
 23. Ollech JE, Rubin DT, Glick L, Weissshof R, El Jurdi K, Israel A, et al. Ustekinumab is effective for the treatment of chronic antibiotic-refractory pouchitis. *Dig Dis Sci.* 2019;64(12):3596-3601. doi: 10.1007/s10620-019-05697-1.
 24. Kato S, Sakakibara Y, Ishihara A, Iwasaki T, Tanaka S, Hasegawa H, et al. A case of refractory pouchitis following surgery for ulcerative colitis successfully treated with adalimumab. *Nihon Shokakibyo Gakkai Zasshi.* 2019;116(9):732-738. doi: 10.11405/nisshoshi.116.732.
 25. Seifarth C, Slavova N, Degro C, Lehmann KS, Kreis ME, Weixler B. Sacral nerve stimulation in patients with ileal pouch-anal anastomosis. *Int J Colorectal Dis.* 2021;36(9):1937-1943. doi: 10.1007/s00384-021-03981-z.