



## Case Report

Online ISSN (3219-2789)

### Delayed Presentation of Testicular Seminoma with Normal Biomarkers: A Case Report and Review

Hala Abdulghani Al-Rawi<sup>1</sup>, Wassan Nori<sup>1\*</sup>, Sumaya Alrawi<sup>2</sup>, Shaymaa Khalid Abdulqader<sup>3</sup>,  
 Saad Dakhil Farhan Daraji<sup>4</sup>, Muna Abdul Ghani Zghair<sup>2</sup>

<sup>1</sup>Department of Obstetrics and Gynecology, College of Medicine, Mustansiriya University, Baghdad, Iraq; <sup>2</sup>Department of Radiology, College of Medicine, Mustansiriya University, Baghdad, Iraq; <sup>3</sup>Department of Radiology, Al-Kindy College of Medicine, University of Baghdad, Baghdad, Iraq; <sup>4</sup>Department of Surgery, College of Medicine, University of Baghdad, Baghdad, Iraq

Received: 27 September 2025; Revised: 10 January 2026; Accepted: 27 January 2026

#### Abstract

Seminoma is a prominent subtype of testicular cancer, which is the most prevalent solid tumor in young adult males, for the best patient's outcome, where early diagnosis and management are crucial. Here we describe a male patient, age 22, who had an RT-sided gradual onset painless scrotal swelling for the last six months. On examination, a hard, well-defined intra-testicular mass was felt, which proved to be highly vascular on imaging. Alpha-fetoprotein and  $\beta$ -HCG were within normal range. The provisional diagnosis of seminoma was made, which was confirmed by a histopathological exam, where radical inguinal orchiectomy was performed. The current case emphasizes that although its malignant seminoma produces minimal symptoms, the tumor markers are within normal limits, which adds to the diagnostic challenges. It is important to keep in mind that prompt imaging and surgical management are necessary to achieve better patient outcomes, regardless of normal lab tests. A normal lab test does not exclude malignancy, and the malignant potential has to be kept in mind at the young age group.

**Keywords:** Alpha-fetoprotein;  $\beta$ -HCG; Orchiectomy; Seminoma; Scrotal swelling; Ultrasound.

تأخر عرض ورم الخصية مع علامات حيوية طبيعية: تقرير حالة ومراجعة

#### الخلاصة

السيبيورما هو نوع فرعي بارز من سرطان الخصية، وهو الورم الصلب الأكثر انتشاراً لدى الذكور الشباب، لتحقيق أفضل نتيجة للمرضى يكون التشخيص المبكر والعلاج أمراً حاسماً. هنا نصف مريضاً ذكراً، يبلغ من العمر 22 عاماً، كان يعاني من تورم تدريجي في الصفن غير مؤلم من جانب الأشعة العصبية خلال الأشهر الستة الماضية. عند الفحص، تم الشعور بكتلة صلبة ومحددة جيداً داخل الخصية، والتي ثبت أنها تحتوي على الأوعية الدموية عند التصوير. كان بروتين ألفا الفيتوبروتين و  $\beta$ -HCG ضمن النطاق الطبيعي. تم التشخيص النسيجي الأولي للورم، والذي تم تأكيده بفحص نسيجي مرضي، حيث أجري استئصال الخصية الإربية الجذري. تؤكد الحالة الحالية أنه رغم أن الورم الخبيث لديه ينتج أعراضاً طفيفة، إلا أن علامات الورم ضمن الحدود الطبيعية، مما يزيد من تحديات التشخيص. من المهم أن نضع في الاعتبار أن التصوير السريع والتدخل الجراحي ضروريان لتحقيق نتائج أفضل للمرضى، بغض النظر عن الفحوصات المخبرية العادية. الفحص المخبري الطبيعي لا يستبعد الورم الخبيث، ويجب مراعاة احتمال الإصابة في الفئة العمرية الصغيرة.

\* **Corresponding author:** Wassan Nori, Department of Obstetrics and Gynecology, College of Medicine, Mustansiriya University, Baghdad, Iraq; Email: [dr.wassan76@uomustansiriya.edu.iq](mailto:dr.wassan76@uomustansiriya.edu.iq)

**Article citation:** Al-Rawi HA, Nori W, Alrawi S, Abdulqader SK, Daraji SDF, Zghair MA. Delayed Presentation of Testicular Seminoma with Normal Biomarkers: A Case Report and Review. *Al-Rafidain J Med Sci.* 2026;10(1):115-119. doi: <https://doi.org/10.54133/ajms.v10i1.2515>

© 2026 The Author(s). Published by Al-Rafidain University. This is an open access journal issued under the CC BY-NC-SA 4.0 license (<https://creativecommons.org/licenses/by-nc-sa/4.0/>).



## INTRODUCTION

Seminoma is the most prevalent subtype of germ cell tumors (GCTs); it represents 1/2 of all testicular tumors and is the most frequent malignancy in males aged 15–35 years. They originate from the germinal epithelium and are defined by large, homogeneous cells with central nuclei and transparent cytoplasm [1]. Seminoma has three subtypes: 1-classical (typical), 2-spermatocytic seminoma, and 3-anaplastic seminoma [2]. They are frequently linked to septal fibrosis and lymphocytic infiltrates. The most common presentation is a painless testicular tumor, during which a minority experience discomfort. Scrotal ultrasound is the initial investigation of choice. It shows a hypoechoic homogenous intratesticular lesion. Biochemical markers such as alpha-fetoprotein may be normal in most cases, and  $\beta$ -CG (Beta-Human Chorionic Gonadotropin) may be slightly elevated as

LDH (Lactate Dehydrogenase) serum levels [1,2]. Further seminoma staging includes CT imaging (Computed Tomography), notably CT of the chest, abdomen, and pelvis, which is needed to exclude retroperitoneal lymph node involvement or distant metastases [3]. Seminomas are extremely radiosensitive and chemosensitive, with an excellent prognosis—5-year survival rates reach 95% with adequate treatment, which often includes orchiectomy followed by monitoring, radiotherapy, or chemotherapy, depending on the stage [4].

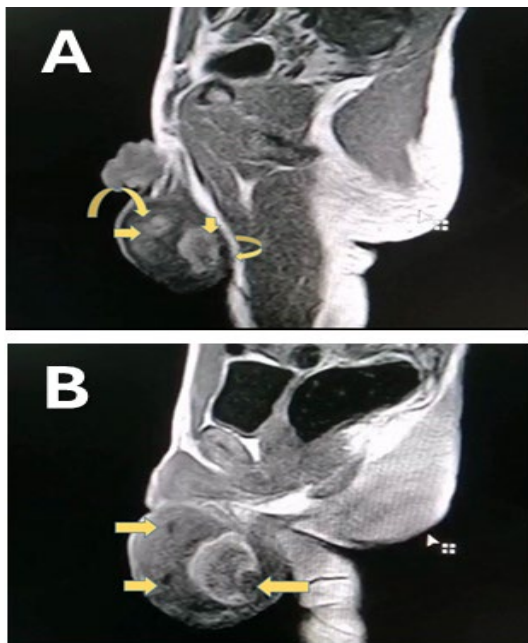
## CASE PRESENTATION

A 22-year-old man in good health arrived at the outpatient clinic with a right-sided scrotal enlargement that was growing without causing any pain. He had sporadic right groin soreness six months earlier, which marked the onset of symptoms. There was a negative

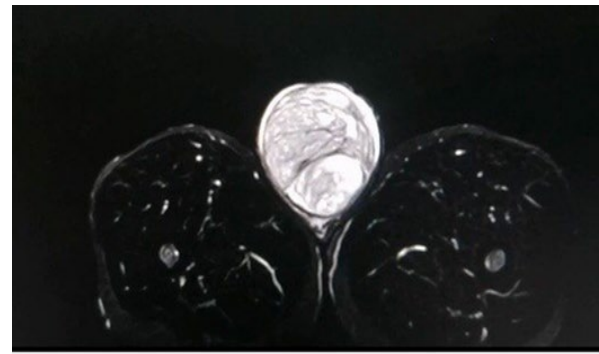history of prior scrotal surgery, lower abdominal or pelvic pain, urinary tract infection, trauma, or systemic symptoms. The patient's increasing scrotal growth led to the discovery of a hard intratesticular lump that became socially distressing and necessitated a doctor's visit. Upon examination, the right testis was noticeably larger, firmer, and less tender, taking up the majority of the testicular volume. There was no transillumination. Gynecomastia, inguinal lymphadenopathy, or local skin abnormalities were not present. Upon palpation, the contralateral testis appeared normal. Abdominal and rectal digital exams revealed that they were unremarkable.

### Diagnostic evaluation

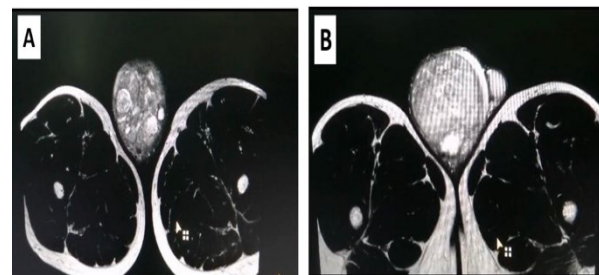
Scrotal ultrasonography revealed a well-defined, heterogeneously hypoechoic mass with increased vascular marking in the right testis, with internal vascularity on color Doppler imaging, raising the possibility of primary testicular cancer. There was no sign of an extratesticular extension or hydrocele. Serum tumor biomarkers showed normal levels of alpha-fetoprotein (AFP) and  $\beta$ -human chorionic gonadotropin ( $\beta$ -hCG), with modest leukocytosis (elevated white blood cell count with neutrophilic predominance). Lactate dehydrogenase (LDH), a generic yet prognostic biomarker, has not been elevated, which usually correlates with the volume of the tumor; it is advised to be included for staging. Abdominal ultrasonography revealed no retroperitoneal lymphadenopathy or visceral involvement. However, a contrast-enhanced MRI of the lower pelvis and scrotum was recommended for further regional evaluation; see Figures 1-3.



**Figure 1:** A Non-contrast sagittal T1 weighted MRI showing a well-defined oval-shaped, heterogeneous mass with multiple variable sizes internal modulations (straight arrows) confined to the scrotum, parts of the tumor are adherent to testicular tunica (curved arrows) Fig. 1 B Contrast-enhanced sagittal T1 weighted MRI showing heterogeneous enhancing scrotal mass with multiple non-enhancing regions which correspond to focal necrotic areas (arrows) reported histopathological.



**Figure 2:** Axial T2 STIR MRI image showing a well-defined mass confined to the scrotum occupying the midline due to its large size, showing internal hyperintense thin septations in relation to the abnormal highlighted testicular surrounding tissue corresponding to histopathological reported fibrous septations.



**Figure 3:** A) axial T2 a. weighted image shows a well-defined mass confined to the scrotal region with internal heterogeneous hyperintense nodules of variable size, which reflect cystic necrotic areas seen in the midline. B) The mass is displacing the normal LT scrotum anteroposteriorly (arrow).

A computed tomography of the chest and abdomen with an i.v contrast study was performed afterward. The study showed a normal mediastinum, and no focal lesion was seen. Normal abdominal and pelvic organs, no para-aortic LAP, abdominal or pelvic free fluid, and no visceral metastasis seen. Pelvic MRI demonstrates a well-defined, enlarged, heterogeneous RT testicular mass with heterogeneous enhancement after IV contrast administration, confined to the scrotum with no obvious extra scrotal extension; see Table 1 for an investigation summary. The differential diagnosis includes testicular seminoma, non-seminoma germ cell tumors, testicular lymphomas, epididymal or paratesticular tumors, and testicular torsion. A preliminary diagnosis of right-sided intratesticular seminoma was made. After complete patient evaluation and fitness for surgery, including taking concerns and considerations, right inguinal radical orchidectomy was decided; owing to the expected risk on fertility, sperm banking was strongly suggested and was done prior to surgery. The patient had a right radical inguinal orchidectomy. Macroscopically, a well-demarcated, solid grey tumor measuring 10 x 8 x 7.5 cm, labeled as RT testis. Microscopically: sheet configuration of clear cell cytoplasm, coagulative necrosis, with inflammatory cells and fibrous septa. Histopathology confirmed a pure classical seminoma, limited to the testis and not invading the arterial or lymphatic systems.

### DISCUSSION

This case describes a 22-year-old male who developed a right-sided painless scrotal enlargement that was eventually identified as classical seminoma.

**Table 1:** Summary of the investigation conducted for the case

Investigation	Finding and results	Interpretation
Serum tumor biomarkers	AFP: Normal β-hCG: Normal LDH: Normal	Normal AFP and β-hCG reduce the likelihood of non-seminomatous germ cell tumors. Normal LDH suggests lower tumor burden; important for staging despite non-specificity.
Complete Blood Count (CBC)	Leukocytosis with neutrophilic predominance	Suggestive of a reactive/inflammatory process; nonspecific
Abdominal Ultrasonography	- No retroperitoneal lymphadenopathy - No visceral organ involvement	Excludes gross metastasis to abdominal organs and lymph nodes.
Pelvic and Scrotal MRI (Contrast-enhanced)	- Well-defined, enlarged heterogeneous right testicular mass - Heterogeneous enhancement post-contrast - No extra-scrotal extension	Confirms testicular origin and localization of mass. No evidence of local invasion.
CT Chest and Abdomen (Contrast-enhanced)	Normal mediastinum - No focal lesion - Normal abdominal and pelvic organs - No para-aortic lymphadenopathy, free fluid, or visceral metastases	Confirms absence of thoracoabdominal metastases; supports localized disease.

Fortunately, despite the large size of the seminoma, it was localized with no distant metastasis, which is unusual for this size. Seminoma is the most prevalent testicular tumor in 20-45-year-old males. The early twenties are at the lower end of the normal age range, which may lead to less clinical suspicion in primary care settings [5]. The current case had a classical presentation in more than one way; to begin with, the tumor is intratesticular, hard, and painless, typical of germ cell tumors. Scrotal ultrasound showed a well-defined heterogeneous vascular mass that was limited to the Rt testis [6]. The lab test was within the normal range, which is typical of seminoma [7]. On the other hand, there were unusual points in the presentation of the case, such as the first delayed presentation for more than 6 months, which was an underreported cause of diagnostic delay. Second, tumor biomarker data, while not incompatible with seminoma, may add to

diagnostic confusion due to their normal range [2]. Importantly, the initial diagnosis, based on abdominal ultrasonography regarding metastasis, was negative in the current cases. However, the US alone is insufficient to rule out retroperitoneal metastases. According to EAU (European Association of Urology) and NCCN (National Comprehensive Cancer Network) standards, contrast-enhanced CT of the chest, abdomen, and pelvis is essential for accurate staging [8]. Finally, lactate dehydrogenase (LDH), a predictive marker used in the IGCCCG (International Germ Cell Cancer Collaborative Group) risk categorization, was not tested preoperatively [9]. The role of biomarkers in seminoma is somewhat limited; we have summed up the currently available biomarkers in germ cell tumors, their current use, and their application in Table 2.

**Table 2:** Biomarkers in testicular tumors: applications, limitations, and suggested roles with supporting references

Biomarker	Current role	Drawbacks	Suggested roles	References
AFP	Diagnosis and follow-up of non-seminoma s tumors	Not elevated in pure seminomas. Its levels increase in other tumors as liver malignancies	Exclusion of seminoma tumors	[10,11]
β-HCG	Diagnostic, staging, and prognostic markers in seminomas and other testicular tumors	Only an increase of 10-25% of seminoma cases; cross-reaction with LH, drugs, and hypogonadism	Supportive marker; advised to be combined with imaging and clinical picture.	[10,12,13]
LDH	Prognostic and staging biomarkers	It can increase inflammatory conditions and in hemolysis. moreover, it has reliability issues	Useful prognostic marker that assesses the tumor burden. not useful in diagnoses	[11,14,12]
PLAP (Placental alkaline phosphatase)	Useful immunohistochemical marker in diagnosis germ cell tumors	It can be elevated in smoker; it has low sensitivity and specificity (not reliable for clinical practice)	Adjuvant histopathological biomarker	[12]
miRNAs as (371a-3p)	Promising biomarker for testicular tumor for the diagnosis, monitoring and prediction recurrence	Still under research (limited data on its long term outcome)	Optimistic biomarkers that aim to increase diagnostic precision and patient follow up	[10,11,15]

This case emphasizes the importance of increasing clinical suspicion of testicular cancer in any young male who presents with a testicular mass, regardless of symptom severity or tumor marker levels. One of the causes of delayed seminoma diagnosis is the normal levels of tumor markers, so a pure reliance on them causes diagnostic delay and diagnostic challenges; additionally, the impact of psychosocial embracement is another issue to address, which emphasizes the

importance of education and awareness, especially among younger ages [16,17]. Imaging studies should go through local exams for proper staging. LDH is advised to be included in the initial workup of seminoma, as it aids in risk stratification and treatment planning [18-20]. Most affected cases suffer reproductive consequences from the treatment, which can be permanent or temporary based on the treatment received: surgical, chemotherapy, radiotherapy, and

retroperitoneal lymph node dissection (RPLND). We have summarized the expected outcome for each modality of the treatment in Table 3 [21-24]. Due to the significant risk of infertility associated with testicular

seminoma, all patients are advised to undergo sperm banking before systemic treatment, especially chemo- or radiotherapy [25].

**Table 3:** The fertility outcome and time frame for fertility retrieval based on the therapeutic strategy

Therapeutic strategy	Fertility outcome and recovery timeline	Key consideration	References
Radical Orchiectomy	If bilateral, permanent azoospermia, If unilateral, then there is minimal effect on fertility; it will return in the short term.	In unilateral cases, possible reduction in sperm counts	[21]
Chemotherapy	Temporal azoospermia in most patients, which will be normalized in half of the cases in 1-2 years	The adverse effect on fertility is dose-dependent, so sperm banking is advised	[22]
Radiotherapy	Radiation will suppress spermatogenesis; the expected time to retain fertility is 2-3 years.	Adverse effects on fertility are dose- and shield dependence	[23]
RPLND	Injury of the nerve is common here, especially in non-seminoma tumors, leading to retrograde ejaculation. The prognosis depends on the degree of nerve injury.	The nerve-sparing technique can avoid the adverse effect on the nerves.	[24]

Cryopreservation can be done before or immediately after orchiectomy, and systemic treatment is advised according to the European Association of Urology (EAU) guideline 2023 [26]. It is noteworthy that many of the patients were able to father children naturally following the treatment in approximately 75% of the cases who recovered spermatogenesis. As for those who experienced persistent oligospermia or azoospermia, they were managed by assisted reproductive technique ICSI with successful outcomes among many of them [27-29].

## Conclusion

For a better patient outcome, seminomas should be identified and staged early. Psychosocial factors, such as stigma, fear, or lack of awareness, can delay prompt presentations and management, leading to late presentation and distant metastases. These cases emphasize the significance of comprehensive diagnostic workup via imaging and comprehensive clinical evaluation. Although tumor markers were negative, the tumor was actually growing, and fortunately, it was captured before distant metastasis occurred, which is unusual for a big-sized tumor like the one described here. Equally important is addressing fertility preservation. And the outcome is of paramount important, sperm banking is highly recommended, which will not only protect the patient's future reproductive potential but also provide psychological reassurance during treatment planning.

## Conflict of interests

The authors declared no conflict of interest.

## Funding source

The authors did not receive any source of funds.

## Data sharing statement

Supplementary data can be shared with the corresponding author upon reasonable request.

## REFERENCES

- Katabathina VS, Vargas-Zapata D, Monge RA, Nazarullah A, Ganeshan D, Tammiseti V, et al. Testicular germ cell tumors: classification, pathologic features, imaging findings, and management. *Radiographics*. 2021;41(6):1698–1716. doi: 10.1148/rg.2021210024.
- Ruf CG, Isbarn H, Wagner W, Fisch M, Matthies C, Dieckmann KP. Changes in epidemiologic features of testicular germ cell cancer: age at diagnosis and relative frequency of seminoma are constantly and significantly increasing. *Urol Oncol*. 2014;32(1):33. doi: 10.1016/j.urolonc.2012.12.002.
- Pierre T, Selhane F, Zareski E, Garcia C, Fizazi K, Loriot Y, et al. The role of CT in the staging and follow-up of testicular tumors: baseline, recurrence and pitfalls. *Cancers (Basel)*. 2022;14(16):3965. doi: 10.3390/cancers14163965.
- Tavares NT, Henrique R, Bagrodia A, Jerónimo C, Lobo J. A stroll through the present and future of testicular germ cell tumour biomarkers. *Expert Rev Mol Diagn*. 2023;23(5):405–418. doi: 10.1080/14737159.2023.2206956.
- De Visschere P, Bertolotto M, Belfield J, Campo I, Corcioni B, Derchi L, et al. Abdominopelvic imaging in the follow-up of testicular germ-cell tumors in adults: recommendations of the Scrotal and Penile Imaging Working Group of the European Society of Urogenital Radiology. *Eur Radiol*. 2025;1. doi: 10.1007/s00330-025-11380-z.
- Sangüesa C, Veiga D, Llavador M, Serrano A. Testicular tumours in children: an approach to diagnosis and management with pathologic correlation. *Insights Imaging*. 2020;11:1–4. doi: 10.1186/s13244-020-00867-6.
- Pedrazzoli P, Rosti G, Soresini E, Ciani S, Secondino S. Serum tumour markers in germ cell tumours: From diagnosis to cure. *Crit Rev Oncol Hematol*. 2021;159:103224. doi: 10.1016/j.critrevonc.2021.103224.
- Oldenburg J, Berney DM, Bokemeyer C, Climent MA, Daugaard G, Gietema JA, et al. Testicular seminoma and non-seminoma: ESMO-EURACAN Clinical Practice Guideline for diagnosis, treatment and follow-up. *Ann Oncol*. 2022;33(4):362–375. doi: 10.1016/j.annonc.2022.01.002.
- Murez T, Fléchon A, Branger N, Savoie PH, Rocher L, Camparo P, et al. French AFU Cancer Committee Guidelines—Update 2024–2026: Testicular germ cell cancer. *French J Urol*. 2024;34(12):102718. doi: 10.1016/j.fjurol.2024.102718.
- Bagrodia A, Daneshmand S, Cheng L, Amatruda J, Murray M, Lafin J. The past and future of biomarkers in testicular germ cell tumors. *Soc Int Urol J*. 2020;1(1):77–84. doi: 10.48083/RZEQ2256.
- Murray MJ, Huddart RA, Coleman N. The present and future of serum diagnostic tests for testicular germ cell tumours. *Nat Rev Urol*. 2016;13(12):715–725. doi: 10.1038/nrurol.2016.170.
- Mann K. Tumor markers in testicular cancer. *Der Urologe Ausg A*. 1990;29(2):77–86. PMID: 2158684.
- Gilligan TD, Seidenfeld J, Basch EM, Einhorn LH, Fancher T, Smith DC, et al. ASCO guideline: uses of serum tumor markers in adult males with germ cell tumors. *J Clin Oncol*. 2010;28(20):3388–3404. doi: 10.1200/JCO.2009.26.4481.

14. Szymendera JJ, Zborzil J, Sikorowa L, Kamińska JA, Gadek A. Value of five tumor markers (AFP, CEA, hCG, hPL and SP1) in diagnosis and staging of testicular germ cell tumors. *Oncology*. 1981;38(4):222–229. doi: 10.1159/000225555.
15. Aghamir SM, Ghajar HA, Zadeh ZK, Taheri D. Biology of cancer. In: Aghamir SMK, editor. *Genetics and Epigenetics of Genitourinary Diseases*. Cambridge (MA): Academic Press; 2025. p.181–197. doi: 10.1016/B978-0-443-27302-5.00013-9.
16. Gercek O, Topal K, Yildiz AK, Ulusoy K, Yazar VM. The effect of diagnosis delay in testis cancer on tumor size, tumor stage and tumor markers. *Actas Urol Esp*. 2024;48(5):356–363. doi: 10.1016/j.acuroe.2023.11.004.
17. Kälın M, Mauti L, Pless M. Testicular cancer: Diagnostics, therapy and follow up. *Praxis*. 2016;105(11):643–648. doi: 10.1024/1661-8157/a002364.
18. Powles T, Bascoul-Mollevi C, Kramar A, Lorch A, Beyer J. Prognostic impact of LDH levels in patients with relapsed/refractory seminoma. *J Cancer Res Clin Oncol*. 2013;139:1311–1316. doi: 10.1007/s00432-013-1442-0.
19. Singla N, Bagrodia A, Baraban E, Fankhauser CD, Ged YMA. Testicular germ cell tumors: A review. *JAMA*. 2025;333(9):793–803. doi: 10.1001/jama.2024.27122.
20. Swadi A, Majid AY, Daraji SD, Mahmood HG. Role of NMP22 and major trace elements in diagnosis of bladder cancer. *Ann Trop Med Public Health*. 2020;23(S16):SP231605. doi: 10.36295/ASRO.2020.231605.
21. Pang KH, Fallara G, Lobo J, Alnajjar HM, Sangar V, von Stempel C, et al. Management of small testicular masses: a Delphi consensus study. *Eur Urol Oncol*. 2025;8(1):152–163. doi: 10.1016/j.euo.2024.10.010.
22. Parekh NV, Lundy SD, Vij SC. Fertility considerations in men with testicular cancer. *Transl Androl Urol*. 2020;9(Suppl 1):S14–23. doi: 10.21037/tau.2019.08.08.
23. Fukunaga H, Yokoya A, Prise KM. A brief overview of radiation-induced effects on spermatogenesis and oncofertility. *Cancers (Basel)*. 2022;14(3):805. doi: 10.3390/cancers14030805.
24. D'Costa S, Kotecha P, Rajan P. Lymph node dissection in testicular cancer: Indications and techniques. *UroCancer Clin India*. 2024;2(3):144–148. doi: 10.4103/UCCI.UCCI\_1\_25.
25. Okada K, Fujisawa M. Recovery of spermatogenesis following cancer treatment with cytotoxic chemotherapy and radiotherapy. *World J Mens Health*. 2019;37(2):166–174. doi: 10.5534/wjmh.180043.
26. Patrikidou A, Cazzaniga W, Berney D, Boormans J, de Angst I, Di Nardo D, et al. European Association of Urology guidelines on testicular cancer: 2023 update. *Eur Urol*. 2023;84(3):289–301. doi: 10.1016/j.eururo.2023.04.010.
27. Nori W, Helmi ZR. Can follicular fluid 8-oxo-2'-deoxyguanosine predict the clinical outcomes in ICSI cycle among couples with normospermia male? *Obstet Gynecol Sci*. 2023;66(5):430. doi: 10.5468/ogs.22170.
28. Muhammad Zaki S, Akil Kh Al-Daoudy A, Shawket Kawther R. Comparison study in seminal fluid between the cigarette smoker and the non-smoker among infertile males in Erbil city. *Kirkuk J Med Sci*. 2021;4(1):36–45. doi: 10.32894/kjms.2021.169465.
29. Takeshima T, Mimura N, Aoki S, Saito T, Karibe J, Usui K, et al. Pre- and post-chemotherapy spermatogenesis in male patients with malignant bone and soft tissue tumors. *Front Pharmacol*. 2023;14:1324339. doi: 10.3389/fphar.2023.1324339.