

Al-Rafidain J Med Sci. 2025;8(1):173-175.
DOI: <https://doi.org/10.54133/ajms.v8i2.1659>



Online ISSN (2789-3219)

Case Report

Rare Case of Urethral Stricture Presentation in Erdheim-Chester Disease

Viraj Ashok Pawar¹ , Biswanu Sundar Biswal^{1*} , Sanjibani Sudha² , Suren Kumar Das¹ 

¹Department of Urology, IMS & SUM Hospital, Siksha O Anusandhan (Deemed to be University), Bhubaneswar, Odisha, India; ²Department of Plastic Surgery, IMS & SUM Hospital, Siksha O Anusandhan (Deemed to be University), Bhubaneswar, Odisha, India

Received: 6 January 2025; Revised: 30 April 2025; Accepted: 1 June 2025

Abstract

Erdheim-Chester disease is multisystemic involvement of almost all organs and tissues of the body by excessive production of white blood cells by histiocytes. This present case showed the involvement of the urological system in bilateral swollen kidneys, which was seen in both ultrasound as well as contrast computed tomography. Renal parameters and urine culture were normal. Uroflowmetry showed signs of stricture, which was confirmed through retrograde urethrography. There were no clinical signs of other systemic involvement. Radiological examinations were conducted, which showed asymptomatic involvement of sclerosis in bilateral knees. To confirm, further bone biopsy was performed, which had foamy histocyte infiltration along with Touton-like giant cells on immunohistochemistry. Though the prognosis of this disease is poor, early diagnosis and alleviating symptoms require accurate judgment by clinicians in multidisciplinary teamwork.

Keywords: Erdheim-Chester disease, Histiocytosis, Subcapsular, Urethral stricture.

حالة نادرة من تضيق مجرى البول في مرض إردايم تشيستر

الخلاصة

مرض إردايم تشيستر هو حالة تصيب العديد من الأجهزة لجميع أعضاء وأنسجة الجسم تقريباً عن طريق الإنتاج المفرط لخلايا الدم البيضاء بواسطة الخلايا النسيجية. أظهرت هذه الحالة الحالية إصابة جهاز المسالك البولية في الكلى المتورمة الثنائية، والتي شوهدت في كل من الموجات فوق الصوتية وكذلك التصوير المقطعي المحوسب المتباين. كانت المعلمات الكلوية وفحص البول طبيعية. أظهر فحص مجرى البول علامات التضيق، والتي تم تأكيدها من خلال تخطيط الإحليل الرجعي. لم تكن هناك علامات سريرية على إصابة جهاز آخر. تم إجراء فحوصات إشعاعية أظهرت وجود التصلب بدون أعراض في الركبتين الثنائيتين. للتأكد، تم إجراء مزيد من خزعة العظام، والتي كانت تحتوي على تسلسل خلية التشریح الرغوية جنباً إلى جنب مع الخلايا العملاقة الشبيهة بتوتون في الكيمياء المناعية. على الرغم من أن تشخيص هذا المرض ضعيف، إلا أن التشخيص المبكر وتخفيف الأعراض يتطلب حكماً دقيقاً من قبل الأطباء في العمل الجماعي متعدد التخصصات.

* **Corresponding author:** Biswanu S. Biswal, Department of Urology, IMS & SUM Hospital, Siksha O Anusandhan (Deemed to be University), Bhubaneswar, Odisha, India; Email: biswanusundarbiswal@soa.ac.in

Article citation: Pawar VA, Biswal BS, Sudha S, Das SK. Rare Case of Urethral Stricture Presentation in Erdheim-Chester Disease. *Al-Rafidain J Med Sci.* 2025;8(2):173-175. doi: <https://doi.org/10.54133/ajms.v8i2.1659>

© 2025 The Author(s). Published by Al-Rafidain University College. This is an open access journal.



INTRODUCTION

The rare aggressive multisystem form of non-Langerhans' cell histiocytosis known as Erdheim-Chester disease (ECD) was initially explained by Jakob Erdheim and William Chester in 1930 [1]. The clinical hallmarks of the disease include excess and abnormal production of white blood cells, termed histiocytes, in many organs and tissues. Many internal organs and tissue sites, such as the long tubular bones, skin, lung, pericardium, kidney, retroperitoneal space, orbit, and brain, are affected by xanthogranulomas, which are produced by lipid-laden histiocytes [2,3]. Urological manifestations, such as perirenal fat infiltration, hydronephrosis, and renal sinus involvement, have been reported [4]. For ECD there is no set course of treatment. Different treatment plans have been tested, including some conventional medications and, more recently, targeted therapies.

Case Summary

A 52-year-old male with a known case of hypertensive disorder along with type 2 diabetes mellitus under treatment in the last 5 years was presented in the emergency department with pain in the abdomen, vomiting, and dysuria. There was a history of straining while micturition. His physical examination was otherwise unremarkable. Blood work was suggestive of raised erythrocyte sedimentation rate (ESR) and C-reactive protein (CRP), which was suggestive of inflammation. Complete blood count showed microcytic hypochromic anemia. Blood and urine cultures were negative, but the renal functions were normal. The ultrasound of the abdomen and pelvis showed bilateral swollen kidneys with a hypochoic ring in the perinephric region. Contrast-enhanced computed tomography was done to further evaluate, which was suggestive of bilateral perinephric or subcapsular enhancing and soft tissue extending into the hilum, perivascular plaque-like enhancing soft tissue along

the celiac trunk, superior mesenteric artery (SMA), and common hepatic artery (CHA) causing its mild luminal narrowing along with splenic infarcts with a

bulky pancreas with patchy areas of parenchymal hypo-enhancement along with multiple lymph node enlargements (Figure 1).

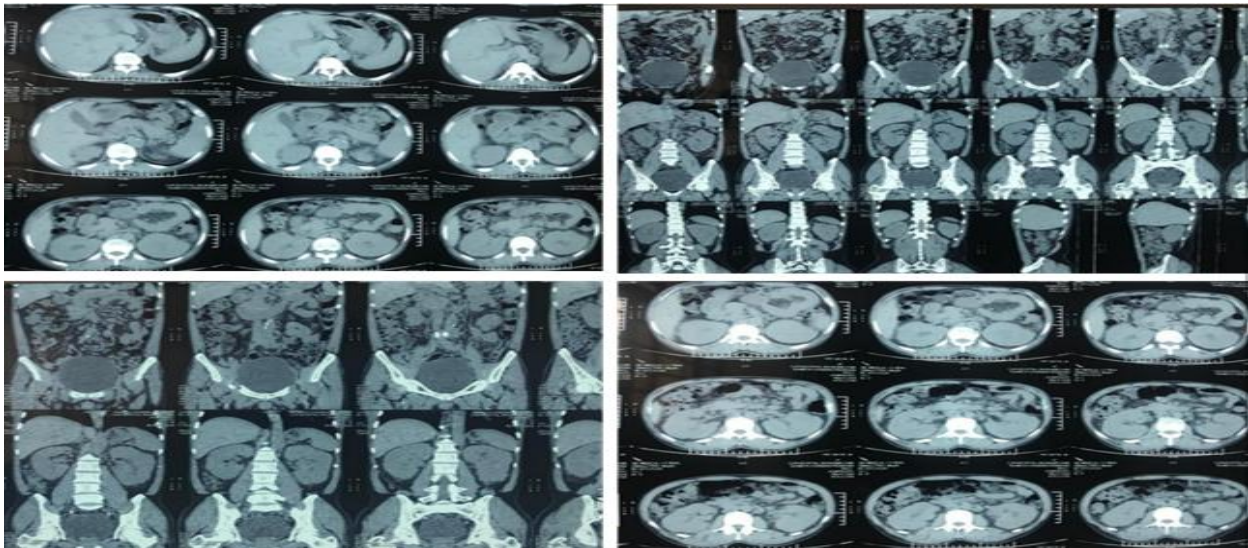


Figure 1: Bilateral swollen kidneys with hypoechoic ring in perinephric region.

The above computed tomography finding was commonly seen with the differential diagnosis of Erdheim-Chester disease. Furthermore, Evaluation of the endocrine function was done, which showed raised HbA1c with other parameters that were normal as well as complement C3 and C4 that were normal. Uroflowmetry was suggestive of a stricture pattern, and that was confirmed on retrograde urethrogram (Figure 2).

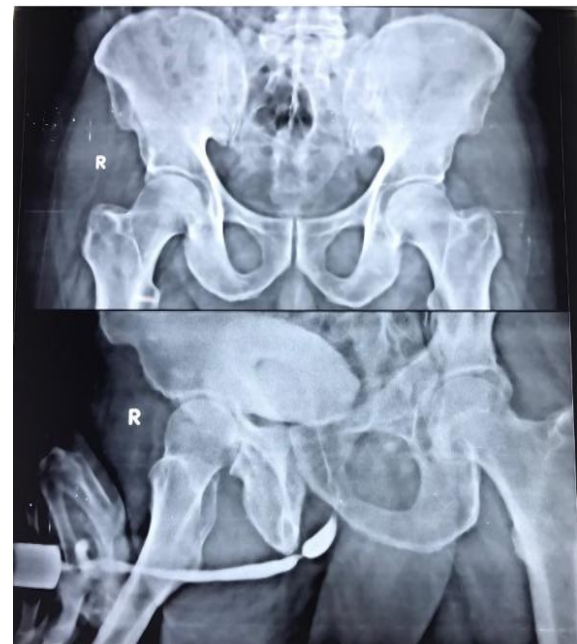

Figure 3: RGU showing bulbar urethral stricture.

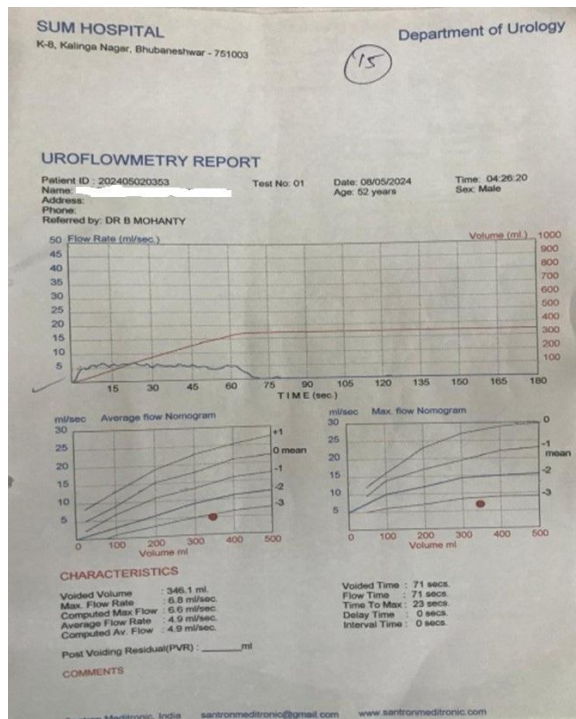


Figure 2: Uroflowmetry showing stricture pattern.

Though the patient was asymptomatic with no bone pain. The patient had radiological examinations, including a bilateral knee X-ray that revealed bilateral sclerotic alterations in the femur and tibial bones (Figure 3).

It was found that the bone biopsy had diffuse foamy histiocyte infiltration, fibrosis, and rare Touton-like giant cells (Figure 4). The immunohistochemistry (IHC) profile was consistent with ECD, without any granulomas, and negative for carcinoma. These findings support the diagnosis of ECD with rare urological manifestation of bulbar urethral stricture along with asymptomatic bony manifestation.

DISCUSSION

To date, ECD remains an uncommon and incurable illness that affects multiple systems. It primarily affects the lower and upper bones, the orbit, and the central nervous system, with a strong correlation between the disease and the site of infiltration. The most typical initial presentation is skeletal involvement [4].

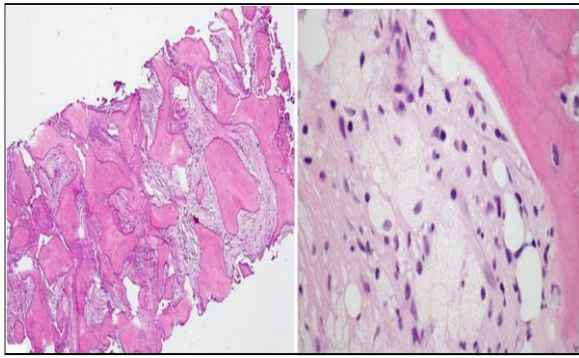


Figure 4: Bone biopsy showing foamy diffuse histiocytes and Touton cells.

Retroperitoneal fibrosis is the main cause of ureteral obstruction in ECD. In a retrospective analysis of 24 ECD patients with various urological symptoms, it was found that 14 of the cases involved the proximal ureter [5]. But in this case, patients presented with urethral stricture, and later investigation found them to have ECD. Further, in this patient, there was a microcytic hypochromic blood picture, which could be due to the infiltrative nature of ECD. Even inflammatory markers CRP and ESR were raised. ECD is shown to exhibit inflammatory myeloid neoplasm. Another striking feature of ECD is affection in appendicular bones rather than axial. Our patient has similar bony involvement, though it was an incidental finding, as the patient was asymptomatic. Clinical features, imaging features, and histological confirmation are combined to establish the ECD diagnosis [6]. Though a molecular profile is required, the patient could not undergo the same due to financial constraints, which is one of the limitations in this study. ECD is a rare disease, so there is no consensus guideline for treatment.

Conclusion

Due to the wide range of symptoms and lack of information about this rare illness, clinical suspicion plays an important role in the diagnosis process.

Though kidneys are the most affected urological visceral organ in ECD, in our case it was stricture at the bulbar urethra due to which the patient presented with voiding complaints. Detailed radiological investigation and biopsy act as an aid to diagnose ECD in this patient.

Conflict of interests

No conflict of interest was declared by the authors.

Funding source

The authors did not receive any source of funds.

Data sharing statement

Supplementary data can be shared with the corresponding author upon reasonable request.

REFERENCES

1. Pan A, Doyle T, Schlup M, Lubeke R, Schultz M. Unusual manifestation of Erdheim-Chester disease. *BMC Gastroenterol.* 2011;11:77. doi: 10.1186/1471-230X-11-77.
2. Veyssier-Belot C, Cacoub P, Caparros-Lefebvre D, Wechsler J, Brun B, Remy M, et al. Erdheim-Chester disease clinical and radiologic characteristics of 59 cases. *Medicine.* 1996;75(3):157-169. doi: 10.1097/00005792-199605000-00005.
3. Lim J, Kim KH, Suh KJ, Yoh KA, Moon JY, Kim JE, et al. A unique case of Erdheim-Chester disease with axial skeleton, lymph node, and bone marrow involvement. *Cancer Res Treat.* 2016 Jan 1;48(1):415-421. doi: 10.4143/crt.2014.160.
4. Wu Z, Jiang GL, Tang Y, Jiang C, Sun LL, Li N, et al. Urinary involvement in Erdheim-Chester disease: computed tomography imaging findings. *Abdomin Radiol.* 2021;46(9):4324-4331. doi: 10.1007/s00261-021-03106-8.
5. Haroche J, Cohen-Aubart F, Charlotte F, Maksud P, Grenier PA, Cluzel P, et al. The histiocytosis Erdheim-Chester disease is an inflammatory myeloid neoplasm. *Expert Rev Clin Immunol.* 2015;11(9):1033-1042. doi: 10.1586/1744666X.2015.1060857.
6. Munoz J, Janku F, Cohen PR, Kurzrock R. Erdheim-Chester disease: characteristics and management. *Mayo Clin Proc.* 2014;89(7):985-996. doi: 10.1016/j.mayocp.2014.01.023.